INTERNATIONAL JOURNAL *of* PEDIATRIC DERMATOLOGY

Official Journal of the World Health Academy of Dermatology and Pediatrics

Special Issue
XXV CONGRESS
Dermatology for the Pediatrician
Riccione, Italy | May 23–24, 2025

Contents

Editorial 1

The Three Most Important Things to Tell Parents of a Newborn/Infant with:

The Three Most Important Things to Tell Parents of a Newborn/Infant with a Problem of the Navel..... 2
Giorgio Rovatti

The Three Most Important Things to Tell Parents of a Newborn/Infant with a Napkin Dermatitis..... 6
Annalisa Franch and Fabio Arcangeli

The Three Most Important Things to Tell Parents of a Newborn/Infant with a Candida infection..... 12
Patrizio Mulas

The Three Most Important Things to Tell Parents of a Newborn/Infant with a Congenital Melanocytic Nevus..... 16
Fabio Arcangeli

The Three Most Important Things to Tell Parents of a Child With Café-au-lait Macules..... 20
Laura Ciulli

The Three Most Important Things to Tell the Parents of a Child with Atopic Dermatitis..... 24
Francesco Mazzotta

The Three Most Important Things to Tell Parents of a Newborn/Infant with Scabies..... 27
Giuseppe Ruggiero

The Three Most Important Messages for Parents of a Child with Facial Infantile Hemangioma..... 32
Andrea Diociaiuti

Management Strategies for:

How to Manage a Severe Urticaria……..... 36
Francesca Mori

Syphilis Disease and Teens: What Parents Need to Know and What They Need to Be Sure Their Teens Know..... 40
Sara Poggiali and Roberta Bilenchi

How to Manage Suspected Child Abuse..... 44
Fabio Arcangeli

How to Manage Juvenile Acne..... 49
Marialisa Feliciangeli
Vitiligo in Childhood: Being There for the Young Patients and Their Families..... 54
Evridiki Tsoureli-Nikita
Pityriasis Rosea..... 58
Matteo Ferrara

Updates in Pediatric Dermatology:

Current Advances in Photoprotection..... 63
Annalisa Patrizi
Redox Imbalance and the Skin: A Clinical Indicator of Hidden Systemic Risk..... 68
Michele Piazza, Carlo Capristo, Nunzia Maiello and Attilio L. Boner
Gynecological Dermatology in Pediatric Age: A Comprehensive Overview…..... 88
Maria Borodina, Julia Sigova, Yan Valle, Torello Lotti and Fabio Arcangeli
Nickel Allergy in Children and Adolescents: Between Myth and Reality..... 99
Massimo Gola and Manfredi Magliulo
Which Foods Can Be Beneficial in Dermatology?..... 103
Diego Peroni, Alessia Pieri and Alessandra Buononato
New Therapies for Moderate-to-Severe Atopic Dermatitis in Pediatric Patients..... 106
Andrea Conti and Federico Tartari

Cold Cases in Pediatric Dermatology:

Eye for an Eye… Herpes Zoster Ophthalmicus in Two Children..... 111
Maddalena Milioni
Persistent Congenital Hemangioma..... 115
Amalia Licordari
What Strange Spots!..... 119
Maria Manta
Is Alopecia Always Areata?..... 123
Antonio Iannone
Marine Irritants. Two Case Reports..... 127
Flavio Magliani

Editorial

Celebrating 25 Years of Excellence in Pediatric Dermatology: Insights and Future Perspectives from the National Congress

Fig. 1. *The plenary session of the 25th National Congress "Dermatology for Pediatricians" held in Riccione. The 2025 edition focused on the theme "Mom, Tell Me About the Future".*

The National Congress ***"Dermatology for Pediatricians"***, now in its 25th year, has been held almost annually since 1997. It is primarily addressed to both private and hospital pediatricians, with the goal of promoting practical scientific training aimed at improving the quality of diagnostic and therapeutic interventions in the management of major childhood skin conditions.

Over the years, the Congress has attracted an increasing number of participants, thanks in part to its practical and highly interactive format. The most recent edition, *"**Mom, Tell Me About the Future**"*, welcomed more than 1,500 attendees.

This year, we have chosen to collect the contributions of the speakers, whom we sincerely thank for their patient and dedicated work, in a Special Issue of the *International Journal of Pediatric Dermatology*. We hope that it will meet the appreciation of our readers.

This Special Issue aims not only to document the present state of pediatric dermatology but also to inspire future generations of clinicians and researchers.

Fig. 2. *Record-breaking attendance, with over 1,500 pediatricians and specialists engaged in highly interactive workshops.*

Fabio Arcangeli

President, National Congress "*Dermatology for Pediatricians"*

Editor-in-Chief of *the International Journal of Pediatric Dermatology*

INTERNATIONAL JOURNAL
of PEDIATRIC DERMATOLOGY

Special Issue, 2025
ISSN 3035-1006 online

Narrative Review

The Three Most Important Things to Tell Parents of a Newborn/Infant with a Problem of the Navel

Giorgio Rovatti[1]

[1]*Private Practice, Modena, Italy*

KEYWORDS

Newborn's navel,
Umbilical stump,
Cord,
Cord care,
Umbilical granuloma,
Umbilical polyp,
Omphalytis,
Umbilical hernia

ABSTRACT

The Author briefly reviews the physiological involution of the umbilical stump, the commonly accepted practices of cord care and the pathological conditions of the navel in neonatal age and the first months of life.

CORRESPONDING AUTHOR

Giorgio Rovatti
Pediatrician
Private Practice,
Modena, Italy

grovatti@outlook.it

Copyright 2025 © by World Health Academy Publishing House
This publication and/or article is for individual use only and may not be further reproduced without written permission from the copyright holder.
Unauthorized reproduction may result in financial and other penalties
DISCLOSURE: ALL AUTHORS REPORT NO CONFLICTS OF INTEREST RELEVANT TO THIS ARTICLE.

Introduction

The umbilical cord, an essential connection between mother and fetus in intrauterine life, loses much of its importance when it is cut in the delivery room; It becomes a source of doubt and concern for the newborn's family when the stump remains visible and persists over time.

The present dissertation is dealing with the most common problems of the umbilical region that can be found in newborns and infants in the first months of life.

The umbilical cord stump undergoes a progressive shriveling and drying, final outcome of a series of physiological processes leading to its separation. This involution is thought to be initiated by thrombosis and contraction of the umbilical vessels, followed by necrosis-inducing granulocyte and macrophage migration (1).

Timing of cord separation

The mean umbilical cord separation time is 6.61 days (±2.33- Min1,97-Max 13,96) (2, 4).

Even though there is not an universally accepted definition, it is usually believed that a cord separation after 2-3 weeks from birth can be considered to be delayed (2, 3).

Many factors can be associated with delayed separation of the umbilical cord stump, such as prematurity, low birthweight, delivery by cesarean section, systemic antibiotics for neonatal infections and administration of topical antiseptic agents (1, 2, 4, 16).

The vast majority of newborns displaying an umbilical stump whose time of separation is delayed beyond the usual physiological time limits is completely healthy. Nonetheless, a marked delay in cord separation in patients showing umbilical infections and/or recurrent/severe infections, especially involving skin, gums, raises the suspicion of leukocyte adhesion deficiency (LAD) (5).

Leucocyte adhesion deficiency (LAD) syndromes are a group of rare Immunodeficiency disorders consisting in an inability of leukocytes to migrate to the site of infection. The exact prevalence of this disorder is difficult to evaluate given its rarity but, referring to its commonest variant LAD-I, it is estimated to be between 1-9 / 1 000 000ive births (6).

Cord care

Many studies have shown that the application of antiseptics to the umbilical cord stump to prevent infections, while delaying its separation (16), did not provide clear benefit (8). The most widely recommended practice nowadays is the so called "Dry Cord Care" (9) that can be summarised in few simple pieces of advice (7):

• Keep the stump dry and exposed the to air;
Keep the front of your baby's diaper folded down;
• Cover the stump with a sterile gauze and if it becomes soiled, clean it with sterile water;
• Give your baby a sponge bath until the cord falls off.

It has been shown that this kind of cord care does not increases the risk of infections when the delivery takes place in hospital settings and/or in a safe and hygienically suitable environment (8). The WHO recommends application of antiseptics (4% chlorhexidine) only in settings where, for cultural reasons, harmful traditional substances (e.g. animal dung) are commonly used on the umbilical cord (8, 9). Once the umbilical cord stump has fallen off it is not unusual to notice secretions in the umbilical area.

Two distinct situations can be observed:

• ***Secretions <u>without</u> clinical signs of inflammation***

The most prevalent cause of persistent serous or serosanguinous drainage is, by far, the *Umbilical Granuloma*, commonly considered to be the result of an overgrowth of the granulation tissue; it usually looks like a soft pink or light red lump. The umbilical granuloma is not to be confused with *Umbilical Polyp*, remnants of the omphalomesenteric duct enteric mucosa at the umbilicus. Small umbilical granulomas can undergo a spontaneous involution without any intervention (3); nevertheless, cauterization with silver nitrate remains the conventional treatment of umbilical granulomas although they can also be successfully managed at home by using table or cooking salt (10, 11). The results of the latter treatment are satisfactory without the small risks of excessive burning of the former. The incomplete or anomalous involution of the omphalomesenteric duct or the urachus can be rarely responsible for persistent secretions from the navel (3).

• ***Secretions <u>with</u> clinical signs of inflammation***

The most common cause is omphalitis, a potentially serious infection whose incidence is estimated around 0.1% in "high income" countries, where the delivery takes place in safe and hygienically suitable environment; in less favourable conditions the incidence can

reach the 8% (8, 12). The bacterial species isolated in this condition are numerous:Gram positives (*Staphylococcus aureus, Streptococcus pyogenes*), Gram negatives (*Escherichia coli, Klebsiella pneumoniae, Proteus mirabilis*) ed Anaerobis (*Bacteroides fragilis, Clostridium perfringens*) (8, 12).

The clinical spectrum of clinical findings is wide and a classification divided into four stages has been proposed (Table I) (12).

Table I. *Omphalitis classification.*

Omphalitis - Classification
Funisitis and umbilical discharge
Omphalitis with abdominal wall cellulitis
Omphalitis with systemic sepsis
Omphalitis with fasciitis

The treatment of omphalitis in the newborn includes antimicrobial therapy and supportive care that is beyond the scope of this paper.

Umbilical hernia

Umbilical hernias are fairly common among children, with a prevalence ranging from 10% to 30% of newborns (15). It is very common for umbilical hernias to close spontaneously during the first 3 years of life and most will close by 4-6 years of age (14, 15). An expectant management of umbilical hernias is therefore usually advised, given the favourable natural history and the quite low rate of complications (the risk of incarceration is variously estimated in literature, ranging from 0.07% to 2.77%) (13). Surgical repair for asymptomatic hernias is not routinely indicated before the age of 4-5 years (14, 15).

References

1. Anhalt H, Marino RV, Rosenfeld W. Retained umbilical stump: clinical approaches and separation anxiety. Am J Dis Child. 1992; 146(12):1413-4. doi: 10.1001/archpedi.1992.02160240023005.
2. Oudesluys-Murphy AM, Eilers GA, de Groot CJ. The time of separation of the umbilical cord. Eur J Pediatr. 1987; 146(4):387-9. doi: 10.1007/BF00444944. PMID: 3653134.
3. Chabra S, Anderson JA, Jovid PJ. Abdominal wall defects in: Avery's diseases of the newborn Edited by Christine A. Gleason and Sandra E. 11th Edition-Elsevier 2024.
4. López-Medina MD, López-Araque AB, Linares-Abad M, López-Medina IM. Umbilical cord separation time, predictors and healing complications in newborns with dry care. PLoS One. 2020; 15(1).
5. Reynolds S, Devlia D, Stearns R, Cole T. Should all infants with delayed umbilical cord separation be investigated for leucocyte adhesion deficiency? Arch Dis Child. 2021; 106(12):1233-1236.
6. Orphanet website https://www.orpha.net. Accessed June 2025.
7. Mayo clinic website accessed june2025https://www.mayoclinic.org/healthy-lifestyle/infant-and-toddler-health/in-depth/umbilical-cord/art-20048250.
8. Stewart D, Benitz W; Committee on fetus and newborn. Umbilical Cord Care in the Newborn Infant. Pediatrics. 2016; 138(3):e20162149. doi: 10.1542/peds.2016-2149. PMID: 27573092.
9. WHO recommendations on maternal and newborn care for a positive postnatal experience Geneva: World Health Organization; 2022.
10. The Sydney Children's Hospitals Network website accessed june2025 https://www.schn.health.nsw.gov.au/umbilical-granuloma-factsheet.
11. Banerjee A, Jain RA, Munghate GS, Bodhanwala M, Bendre PS. Common Salt versus Silver Nitrate for the Treatment of Umbilical Granuloma in Infants: An

Open-label, Single-center, Pilot Randomized Controlled Trial. J Indian Assoc Pediatr Surg. 2024; 29(3):199-203. doi: 10.4103/jiaps.jiaps_209_23.
12. Sawardekar KP. Changing spectrum of neonatal omphalitis. Pediatr Infect Dis J. 2004; 23(1):22-6. doi: 10.1097/01.inf.0000105200.18110.1e.
13. Abdulhai SA, Glenn IC, Ponsky TA. Incarcerated Pediatric Hernias. Surg Clin North Am. 2017; 97(1):129-145. doi: 10.1016/j.suc.2016.08.010.
14. Almeflh W et al. Systematic Review of Current Consensus on Timing of Operative Repair Versus Spontaneous Closure for Asymptomatic Umbilical Hernias in Pediatric Med Arch. 2019; 73(4): 268-71
15. Zendejas B, Kuchena A, O Onkedi E et al. Fifty-three–year experience with pediatric umbilical hernia repairs. J Pediatr Surg. 2011, 46(11): 2151-6.
16. Quattrin R, Iacobucci K, De Tina AL et al. 70% Alcohol Versus Dry Cord Care in the Umbilical Cord Care: A Case–Control Study in Italy. Medicine. 2016; 95(14):p e3207.

INTERNATIONAL JOURNAL
of PEDIATRIC DERMATOLOGY

Special Issue, 2025
ISSN 3035-1006 online

Narrative Review

The Three Most Important Things to Tell Parents of a Newborn/Infant with a Napkin Dermatitis

Annalisa Franch[1] and Fabio Arcangeli[2]

[1]*Pediatrician, Bolzano, Italy;*
[2] *Dermatologist, G. Marconi University, Rome, Italy*

KEYWORDS

Diaper dermatitis,
Napkin psoriasis,
Acrodermatitis enteropathica,
Prevention,
Therapy

ABSTRACT

Following the description of the clinical presentation of the principal forms of diaper area dermatitis and the corresponding therapeutic and preventive strategies, the authors briefly outline the key recommendations for parental care of the genital region in neonates and infants.

CORRESPONDING AUTHOR

Annalisa Franch
Pediatrician,
Bolzano,
Italy

dott.franch@gmail.com

Copyright 2025 © by World Health Academy Publishing House
This publication and/or article is for individual use only and may not be further reproduced without written permission from the copyright holder.
Unauthorized reproduction may result in financial and other penalties
DISCLOSURE: ALL AUTHORS REPORT NO CONFLICTS OF INTEREST RELEVANT TO THIS ARTICLE.

Introduction

Diaper dermatitis is an acute inflammation of the skin in the area in contact with the diaper and is one of the most common dermatological conditions in early childhood. It's incidence is relatively high, ranging from 36 to 75 % with severe cases from 1 to 24 % (1) and more than 25% require medical care. If well managed, it tends to be mild and short-lived. Nevertheless, it is almost always a source of great anxiety and concern for parents. It is therefore important that pediatricians or pediatric dermatologists provide clear and helpful information to parents to prevent or promptly manage this condition, and to distinguish it from other dermatitis that may affect the perigenital area.

Diaper dermatitis

True diaper dermatitis is an irritant contact dermatitis. It arises as a result of damage to the skin barrier caused by the occlusive action of the diaper, which creates a warm, humid environment with overhydration of the stratum corneum, and by the action of feces and urine. Fecal bacterial ureases convert urea into ammonia, which increases the pH and activates fecal enzymes. These enzymes further damage the skin barrier already compromised by excess hydration of the stratum corneum (2).

This very common condition may recur from birth up to the age of two, when diapers are typically no longer used. Over 50% of cases are mild and brief, resolving within 2-4 days if properly managed. Severe cases usually result from inadequate management of initially mild symptoms.

Diagnosis is clinical and based on the appearance of bright red erythema, sometimes accompanied by small papules and mild erosions. In the early stages, it mainly affects the convex parts of the diaper area - those most exposed to irritants - while skin folds are usually spared, as they are better protected from direct contact. In this initial phase, the erythema typically forms a W-shaped pattern in girls (Fig. 1) and often an M-shaped pattern in boys.

Fig. 1. *Diaper dermatitis. Involvement of the convex surfaces with sparing of the skin folds. Classic W-shaped pattern.*

Irritant dermatitis with candida superinfection

The warm, humid environment created by the diaper and the damaged skin barrier inevitably promote the proliferation of Candida, which penetrates the stratum corneum and triggers an inflammatory response, worsening the dermatitis. Candida superinfection can be recognized when skin folds are also affected, and when satellite papulo-pustular lesions appear (Fig. 2).

Fig. 2. *Diaper dermatitis with Candida superinfection. Involvement of the convex surfaces and the skin folds, with the presence of papulo-pustular satellite lesions.*

Papulo-erosive dermatitis of Sevestre and Jacquet

When diaper dermatitis is poorly managed, or when severe intestinal conditions cause continuous stool output, extremely serious cases may occur. These are characterized by ulcerative and erosive lesions primarily distributed around the perianal region. Although rare, severe erosive manifestations pose significant diagnostic difficulties and may resemble signs of non-accidental injury (3).

Allergic contact diaper dermatitis

Less common than irritant contact dermatitis, the diaper can occasionally cause allergic contact dermatitis. In such cases, the lesions typically display a characteristic pattern. They are eczematous, almost always bilateral and symmetrical, most often limited to the thighs, specifically the areas in contact with the diaper's edges (Fig. 3) (4). Resolution is usually rapid once the diaper is removed.

Fig. 3. *Allergic contact dermatitis with Candida superinfection.*

Preventing diaper dermatitis

Preventing diaper dermatitis requires care and skill from parents, who should be guided and educated by their pediatrician or pediatric dermatologist. The goal is to preserve the skin's barrier function so that repeated irritant exposure doesn't harm this particularly sensitive area (5).

To achieve this, the following is recommended: gentle cleansing with lukewarm water; careful drying, avoiding rubbing; using warm air if needed; applying a barrier cream at every diaper change. The cream should be safe (free from fragrances, allergens, preservatives, or potential toxins) and effective. It should enhance the barrier function and maintain adequate hydration without being occlusive.

Diapers should be disposable, highly absorbent and breathable, changed every 2–3 hours, preferably after meals.

Treatment of diaper dermatitis

Management of mild diaper dermatitis relies on the same preventive measures, with the possible addition of a topical anti-inflammatory. In vitro and in vivo studies have shown excellent results with the combination of colloidal silver and vitamin D (6). Vitamin D for its anti-inflammatory and reepithelializing effects, and colloidal silver for its antimicrobial properties.

In rare severe forms of diaper dermatitis, treatment may include topical tacrolimus 0.1% as an anti-inflammatory and topical antibiotics such as gentamicin in erosive lesions.

If diaper dermatitis lasts beyond a few days or Candida superinfection is evident, an antifungal - such as an imidazole - can be applied at the first and last diaper change of the day.

Other dermatitis of the diaper area

Other forms of dermatitis may involve the diaper area, either exclusively or alongside other affected regions, and can sometimes mimic true diaper dermatitis. They can be suspected when the skin appearance doesn't match typical diaper rash patterns, when lesions extend beyond the diaper area and when the condition persists more than four days despite proper care.

Napkin Psoriasis

Nearly half of adult psoriasis cases begin within the first two years of life, often affecting the diaper area. Psoriasis may develop at any age and results from genetics combined with triggers such as infection, stress, obesity, or simple friction between skin and diaper.

It occurs in genetically predisposed children, presenting with dry, inflamed, well-defined lesions (Fig. 4), rarely with clearly scaly plaques (Fig. 5). The spread of lesions beyond the diaper area is highly suggestive indicator for diagnosis di Napkin Psoriasis.

Typically, the condition resolves once diaper use ceases, althoug minimal dry lesions may persist. A common site of persistence is the base of the penis.

In uncertain cases, dermoscopy helps clarify the diagnosis: psoriasis reveals silvery scales with a "red dots" carpet-like pattern.

Fig. 4. *Napkin psoriasis. Dry, indurated, and well-demarcated lesions.*

Fig. 5. *Napkin psoriasis. Scaly lesions.*

Acrodermatitis enteropathica

When diaper area dermatitis is accompanied by eczema-like lesions around the mouth, consider Acrodermatitis Enteropathica, a condition caused by zinc deficiency. It can be either acquired, due to malabsorption or malnutrition, or inherited (autosomal recessive), resulting from a deficiency of a protein involved in intestinal zinc absorption.

Oral zinc supplementation consistently leads to rapid clinical improvement.

Three Most Important Things to Tell Parents About Diaper Rash

1. *Keep the area clean and dry:* gently wash the skin with lukewarm water. Dry thoroughly without rubbing, pat gently or use warm air. Use breathable, high-absorbency disposable diapers and change them every 2 - 3 hours, especially after meals.
2. *Use a barrier cream:* choose creams made with safe and effective ingredients - such as a combination of colloidal silver and vitamin D. Avoid overly occlusive products, as they can trap moisture and worsen the rash.
3. *Diaper rash is usually mild and heals in 2 - 4 days with proper care*: if the rash doesn't improve after this period or despite good hygiene practices, reassess the situation with your pediatrician.

References

1. Jaiyeoba O, Visscher MO. Global perspective on the incidence, severity, and management of diaper dermatitis in neonates, infants, and young children. J Tissue Viability. 2025; 34(3):100905. doi:10.1016/j.jtv.2025.100905.
2. Mugita Y, Minematsu T, Nakagami G, Sanada H. Influence of digestive enzymes on development of incontinence-associated dermatitis: inner tissue damage and skin barrier impairment caused by lipidolytic enzymes and proteases in rat macerated skin. Int Wound J. 2018; 15:623-632.
3. Caldas SA, Murphy E, Habeshian K, Kirkorian AY, Hinds T. Ulcerated diaper dermatitis: Child abuse mimicker. Pediatr Dermatol. 2024; 41(1):87-90. doi:10.1111/pde.15374.
4. Di Altobrando A, Gurioli C, Vincenzi C, Bruni F, Neri I. Allergic contact dermatitis caused by the elastic borders of diapers. Contact Dermatitis. 2020; 82:71–72. https://doi.org/10.1111/cod.13401-
5. Kilic FE, Kocak HS, Kaplan Serin E. Traditional practices in the treatment of children with diaper dermatitis. J Tissue Viability. 2024;33(2):190-196. doi:10.1016/j.jtv.2024.03.008.
6. Truzzi F, Tibaldi C, Dilloo S, Saltari A, Levesque MP, Arcangeli F, Garzi A, Ruggiero G, Dinelli G. Topical Administration of Vitamin D2 Combined with Colloidal Silver Nanoparticles Promotes Wound Repair and Protection Against Skin Irritation and UVB Irradiation in 3D Reconstructed Human Skin Models. Pharmaceutics. 2025 Apr 4;17(4):472. doi: 10.3390/pharmaceutics17040472. PMID: 40284467; PMCID: PMC12030705.

INTERNATIONAL JOURNAL
of PEDIATRIC DERMATOLOGY

Special Issue, 2025
ISSN 3035-1006 online

Narrative Review

The Three Most Important Things to Tell Parents of a Newborn/Infant with a Candida infection

Patrizio Mulas[1]

[1]*G. Marconi University, Rome, Italy*

KEYWORDS

Candida
Stomatitis
Oral candidiasis
Genital candidiasis
Vulvovaginitis
Imidazoles

ABSTRACT

This work outlines the spectrum of clinical presentations of Candida infections affecting the mucosal surfaces and skin in pediatric patients.

CORRESPONDING AUTHOR

Patrizio Mulas,
Universty G. Marconi,
Rome, Italy

e-mail: patmulas@gmail.com

Copyright 2025 © by World Health Academy Publishing House
This publication and/or article is for individual use only and may not be further reproduced without written permission from the copyright holder.
Unauthorized reproduction may result in financial and other penalties
DISCLOSURE: ALL AUTHORS REPORT NO CONFLICTS OF INTEREST RELEVANT TO THIS ARTICLE.

Introduction

Candidiasis is a fungal infection caused by yeasts belonging to the genus *Candida*. More than 20 *Candida* species are known to cause infections in humans, the most common of which is *Candida albicans*. *Candida* yeasts are normally part of the intestinal microbiota and can be found on mucosal surfaces and skin without causing disease. *Candida albicans* (CA) is an endogenous microorganism, both commensal and pathogenic, present in 40–80% of individuals. It is the species most frequently associated with superficial candidiasis, although other species may also be involved, including *Candida glabrata, C. tropicalis, C. parapsilosis, C. krusei, C. guilliermondii, C. kefyr, C. rugosa, C. dubliniensis,* and *C. famata*. It is a saprophytic organism commonly found on mucosal and cutaneous surfaces, particularly the oral cavity, gastrointestinal tract, genitourinary tract, conjunctivae, perigenital skin, and large skin folds. Oral colonization may begin in early infancy (≈70% of neonates). CA exhibits a high degree of adaptability to various environmental conditions and can alternate between a quiescent ovoid spore form typical of yeast (Y form) and an active filamentous hyphal form (H form), which is associated with pathogenicity. When host immune tolerance mechanisms are compromised, the Y form transitions to the H form and expresses virulence traits.

Candidiasis

Candida is not normally found on intact skin under physiological conditions. However, it can proliferate and cause infection when the local environment - such as within the oral cavity, pharynx, esophagus, or in skin folds, particularly in the inguinal-genital or axillary regions - undergoes changes that favor yeast growth. The most common clinical manifestations include:

1. **Oropharyngeal Candidiasis.** It presents as solitary or confluent white plaques on the oral mucosa, which may appear erythematous. The tongue may also be affected, showing erythema and loss of lingual papillae (erythematous candidiasis). Treatment. In many patients, topical therapy is effective using amphotericin B, nystatin, or oral miconazole gel (the latter being easier to administer in neonates).
2. **Candida Stomatitis**. Candidiasis that develops in the oral cavity or pharynx is among the most common forms (with a prevalence of approximately 5%), often beginning within the first week of life. The infection typically affects the buccal mucosa, tongue, and hard palate. In more severe cases, it may extend to the pharynx, trachea, and bronchi. Neonatal contamination occurs during passage through the birth canal (1).

Clinical Presentation:

• *Erythematous stomatitis* affecting the gingiva and palate. The mucosa may appear smooth, red, and glazed.
• *Oral thrush* (Fig. 1), characterized by raised whitish plaques on the oral mucosa, sometimes with a curd-like or pseudomembranous appearance. Removal of the plaques reveals a bright erythematous surface.
• *Angular cheilitis* (also known as Perlèche) (Fig. 2), which may be unilateral or bilateral. It often involves the labial commissures, with possible extension to the buccal mucosa, presenting with erythema, maceration, and fissured rhagades (2).
• *Erythematous glossitis*, with loss of lingual papillae. Spontaneous pain or pain during swallowing is frequently reported.

Fig. 1. *Oral Thrush. Tipical whitish plaques on the oral mucosa.*

Fig. 2. *Angular cheilitis.*

3. **Cutaneous Candidiasis.** Cutaneous candidiasis is generally a secondary infection that arises in the context of a pre-existing medical condition. In rare cases, such as diffuse cutaneous candidiasis, it may present as a primary skin infection in neonates (3). The most common form in pediatric patients is localized to the diaper area and presents in two distinct patterns:

• *Primary diaper-area candidiasis* (Fig. 3), characterized by perianal erythema and satellite lesions.
• *Secondary diaper-area candidiasis,* which develops as a superinfection of an underlying irritant contact dermatitis in the diaper region, with satellite lesions extending to the thighs and occasionally to the abdomen.

Fig. 3. *Primary diaper-area candidiasis. Perioriificial erythema and satellite lesions.*

Topical treatment with imidazole derivatives, terbinafine, or nystatin is generally effective. In most cases, concurrent oral administration of nystatin is recommended to reduce intestinal *Candida albicans* colonization.

• **Candida Intertrigo**. Candida intertrigo is an inflammatory dermatosis, often triggered by mechanical or traumatic factors, and typically localized to body folds. Secondary infections by *Candida* species may occur, as these yeasts readily colonize inguinal, perianal, and gluteal regions—especially under conditions of increased local humidity. Clinical presentation includes erythematous, exudative, and macerated areas; confluent erythematous plaques; mild erosions; and peripheral erythematous-pustular lesions.

• **Candida Vulvovaginitis**.*Candida* has been isolated from the vaginal tract in 10–20% of healthy women of reproductive age (4). In 80–92% of vulvovaginitis episodes, *Candida albicans* is identified. In healthy individuals, mucosal surfaces are often colonized by *C. albicans*, whose low population density does not damage epithelial cells nor elicit an inflammatory response. Host immune defenses are typically sufficient and effective. Symptomatic vaginitis, although rare in prepubertal girls (3–6%), occurs when the host's colonization site becomes favorable to yeast proliferation (5). In neonates, the vaginal mucosal epithelium - although only for a few days - shares characteristics with that of women of reproductive age due to identical hormonal stimulation during intrauterine life (6).

Diagnosis:

Detection of fungal antigens: In candidiasis, diagnostic efforts focus on identifying polysaccharide or glycoprotein antigens from the fungal cell wall, as well as intracellular antigens.

Topical Therapy:

Topical antifungal agents are available in various formulations, including solution, lotion, gel, and cream. First-line treatments include imidazole derivatives and ciclopirox olamine. Allylamines are considered second-line options.

Systemic Therapy:

Indicated in cases of multiple or extensive lesions, recurrent infections, or vulvovaginitis. Systemic treatment is essential in immunocompromised patients and in cases of Chronic Mucocutaneous Candidiasis. Itraconazole is the most commonly used agent for yeast infections and those caused by *Aspergillus* species (7).

For mild to moderate oral infections, topical oral antifungals are commonly used, including imidazole derivatives, amphotericin B, and nystatin, along with aqueous sodium bicarbonate solutions, administered for 7–14 days. For severe infections, treatment typical-

ly involves fluconazole at a dosage of 2–7 mg/kg/day, administered either orally or intravenously (8).

The three most important things to tell parents

1. Adopt hygienic and behavioral measures aimed at eliminating local and systemic predisposing factors (e.g., increased humidity, dermatitis, maceration, underlying medical conditions), thereby promoting resolution of the condition and preventing recurrence.

2. Ensure proper skin cleansing, keeping the skin dry. In the diaper area, irritant contact dermatitis and skin maceration can be prevented or minimized through the use of topical barrier agents.

3. To prevent vulvovaginitis, maintain meticulous hygiene, avoid aggressive intimate cleansers and occlusive synthetic underwear, and, when possible, limit prolonged antibiotic therapies.

References

1. Warren RH. Neonatal dermatology. J Am Acad Dermatol. 2004;51:287-8.
2. Kuffer R, Husson C. Chéilites superficielles et perlèche. Ann Dermatol Venereol. 2000;127(1):88-92.
3. Sellami A, Sellami H, Makni F et al. Candidose cutanée en période néonatale. Ann. Dermatol Venereol. 2003;130(4):53.
4. Lorette G. Pathologies vulvaires de l'enfant. Ann Dermatol Venereol. 2003;130(4):33.
5. Larrègue M, Vabres P, Guillet G. Vulvo-vaginites dans l'enfance. Ann Dermatol Venereol. 2004;131(10):889-899.
6. Pierce AM. Vulvovaginitis: causes and management. Arch Dis Child 1992;67(4):509-512.
7. Roderick JH. The management of superficial candidiasis. J Am Acad Dermatol. 1999;40(6Pt2):S35-42.
8. Marialeth R. Infections cutanéo-muqueuses bactériennes et mycosiques. Ann. Dermatol Venereol. 2023;3(7):534:551.

INTERNATIONAL JOURNAL
of PEDIATRIC DERMATOLOGY

Special Issue, 2025
ISSN 3035-1006 online

Narrative Review

The Three Most Important Things to Tell Parents of a Newborn/Infant with a Congenital Melanocytic Nevus

Fabio Arcangeli[1]

[1]*Dermatologist, G. Marconi University, Rome, Italy*

KEYWORDS

Melanocitic nevus,
Congenital nevus,
Cutaneous melanoma risk,
Surgical tratment

ABSTRACT

Congenital melanocytic nevi (CMN) are benign lesions which are typically classified according to their size. The significant attention given to CMN is justified by both aesthetic concerns and the risk of cutaneous melanoma. The author reports the most up-to-date estimates regarding the risk of melanoma and indicates the three most important things to communicate to the parents of a child with a congenital melanocytic nevus.

CORRESPONDING AUTHOR

Prof. Fabio Arcangeli,
Guglielmo Marconi
Univeristy,
Rome, Italy
e-mail:
fabio.arcangeli4@gmail.com

Copyright 2025 © by World Health Academy Publishing House
This publication and/or article is for individual use only and may not be further reproduced without written permission from the copyright holder.
Unauthorized reproduction may result in financial and other penalties
DISCLOSURE: ALL AUTHORS REPORT NO CONFLICTS OF INTEREST RELEVANT TO THIS ARTICLE.

Introduction

Melanocytic nevi (MN) are benign lesions composed of melanocytes, the cells responsible for producing melanin pigment. These melanocytes are typically found in clusters (thecae) arranged along the dermal-epidermal junction, in the demis or in both.

Congenital melanocytic nevi (CMN) develop *in utero* and are usually visible at birth. However, even those that appear in the first months of life (tardive nevi) are considered congenital, especially if their diameter exceeds 1.5 cm.

The significant attention given to CMN, even in childhood, is justified by both aesthetic concerns and the potential for them to evolve into melanoma.

Congenital melanocytic nevi are typically classified according to their projected adult size (1).

1) Giants: maximum diameter greater than 40 cm;
2) Large: maximum diameter between 20 and 40 cm;
3) Medium: maximum diameter between 1.5 and 20 cm;
4) Small: maximum diameter less than 1.5 cm.

The scaling factor used to predict adult size is determined by the anatomical location of the nevus. A CMN located on the head is predicted to grow by a factor of 1.7, on the lower limb by 3.3, and upper limb and torso by 2.8 (2).

Classification by size is justified by the significant differences in clinical, aesthetic, and therapeutic terms, as well as the varying risk of melanoma (Fig. 1).

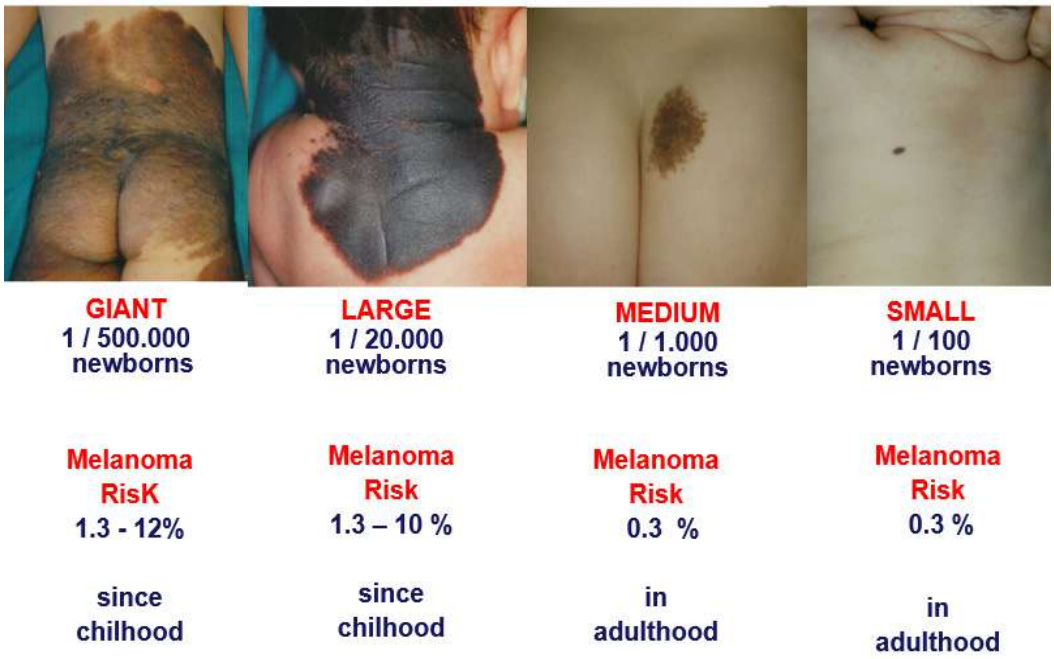

Fig. 1. *Congenital melanocytic nevi classified according to their size.*

Large and Giant Congenital Melanocytic Nevi (LGCMN)

The incidence of Large CMN is estimated at 1:20,000 births, while those Giant, which affect large skin surfaces, sometimes resembling a typical "garment" distribution, have an incidence of 1:500,000 births.

Their colour can vary from light brown to black and is often heterogeneous. The surface can be smooth or irregular, with clear or blurred edges, mostly being irregular. It is common to observe medium or small MN on their periphery or at a distance (*satellite nevi*). Some of these are congenital, while others are acquired.

Over time, LGCMNs can undergo significant changes. They increase in size harmoniously with somatic growth, become darker and more raised. They may cover themselves with terminal hair (sometimes present since birth) and frequently develop papular or nodular *pseudotumoral lesions*, due to deep infiltration of me-

lanocytic cells. In the first years of life, some LGCMNs tend to lighten, especially in skin folds or areas of friction. Those localized on the scalp are particularly prone to spontaneous involution.

LGCMNs, aside from being a potential aesthetic concern, though perhaps less impactful in today's era of widespread tattoos, can give rise to melanoma. Current estimates suggest that melanoma develops at the skin level in fewer than 5% of cases (3), but when considering nervous system involvement, the overall occurrence ranges from 1.3% to 12% of cases (4). Nevi located on the limbs and satellite ones do not appear to have a risk of melanoma.

Neurocutaneous melanocytosis (NCM) - characterized by an increased presence of melanocytic cells in the leptomeninges, brain, and spinal cord - is found in fewer than 7% of patients with LGCMNs and is believed to heighten the risk of melanoma (5).

In more than half of cases melanoma arises before the fifth year of life and originates from melanocytic cells deep within the dermis, leading to nodular lesions. Nodular melanoma is clinically elusive and challenging to detect, as it closely resembles benign nodular formations (*pseudotumoral lesions*) commonly found in LGCMNs. Consequently, diagnosis is often delayed, resulting in a poor prognosis.

LGCMNs should be surgically removed whenever technically feasible, with the primary goals of preserving functionality and achieving aesthetic improvement. However, the extensive size of these nevi often poses a significant limitation to surgical intervention. When direct suture excision, rotation flaps, skin expanders, or dermo-epidermal autografts are not viable options, alternative physical treatments such as dermabrasion, laser therapy, or curettage may be considered.

Neonatal curettage, performed within the first 4–6 weeks of life - when most nevus cells still have a superficial, junctional, distribution - is regarded as a reasonable treatment due to its relative effectiveness and ease of execution (6). The objective of all these treatments is to lower the risk of neoplasia rather than to eliminate it entirely, as numerous melanocytic cells remain in deep tissues and extracutaneous areas. At the same time, they offer the added benefit of aesthetic enhancement.

Careful clinical monitoring should always be scheduled, even following treatment. Due to the inherent challenges in clinical and dermoscopic evaluation - stemming from the frequent morphochromatic irregularities and the presence of hypertrichosis - follow-up should be conducted at specialized centers with expertise in managing LGCMNs.

LGCMNs, particularly those affecting the cervico-cephalic region, may be associated with leptomeningeal melanosis and neurological anomalies, such as congenital neurocutaneous melanosis. For early diagnosis, even in the absence of neurological symptoms, a thorough neurological examination and magnetic resonance imaging are essential.

LGCMNs affecting the lumbosacral region may be accompanied by spinal anomalies, including spina bifida and myelomeningocele.

Medium and Small Congenital Melanocytic Nevi (MSCMN)

These nevi constitute the vast majority of all CMNs and exhibit highly variable clinical appearances. While Medium CMNs are consistently identifiable as congenital - even in the absence of specific anamnestic information - due to their size exceeding 1.5 cm (or 1 cm in young children), Small CMNs cannot be reliably classified as congenital except at birth, as they are morphologically indistinguishable from many acquired melanocytic nevi.

Both Medium and Small CMNs can double in size and undergo changes in shape and color over time. These morphological alterations, particularly common during puberty, are not considered to have pathological significance. The potential development of melanoma within a Medium or Small CMN in adulthood is well-documented, as numerous cases have been reported in the literature. However, the quantitative assessment of this risk remains controversial. Various studies indicate a highly variable incidence of melanoma in MSCMNs, though most authors currently estimate that the risk does not exceed 1%, possibly similar to that of the rest of healthy skin (3, 4, 7).

Unlike LGCMNs, the majority of melanomas associated with MSCMNs develop in adulthood or, at the earliest, after puberty.The surgical removal of these nevi is primarily pursued for aesthetic reasons (Fig. 2) rather than for cancer prevention. In most cases, these procedures are straightforward and highly cost-effective, often performed on an outpatient basis or in a day hospital setting.

Fig. 2. *Surgical removal for aesthetic purposes.*

The three most important things to tell parents

1. Congenital melanocytic nevi are benign lesions with a very low risk of melanoma.

2. Large and Giant nevi require long-term monitoring, preferably at specialized centers. Medium and Small nevi, however, can be safely monitored by a pediatrician or dermatologist.

3. Surgical removal of Medium and Small nevi is optional but can be beneficial - even in preschool-aged children - if aesthetic concerns arise. However, the procedure should always be pursued for cosmetic improvement rather than as an oncological preventive measure, ensuring that aesthetic outcomes are not overlooked.

References

1. Krengel S, Scope A, Dusza SW, Vonthein R, Marghoob AA. New recommendations for the categorization of cutaneous features of congenital melanocytic nevi. J Am Acad Dermatol. 2013; 68:441-51.
2. Kovalyshyn I, Braun R, Marghoob A. Congenital melanocytic naevi. Australas J Dermatol 2009; 50(4):231-40. doi: 10.1111/j.1440-0960.2009.00553_1.x.
3. Scard C, Aubert H, Wargny M, Martin L, Barbarot S. Risk of melanoma in congenital melanocytic nevi of all sizes: a systematic review. J Eur Acad Dermatol Venereol 2023; 37:32-9.
4. Pastore LM, Valentini R, Marghoob AA. Congenital melanocytic nevi and risk of melanoma. Clinics in Dermatology 2025; 43(3):378-384. doi:10.1016/j.clindermatol.2024.09.004
5. Hale EK, Stein J, Ben-Porat L, Panageas KS, Eichenbaum MS, Marghoob AA, Osman I, Kopf AW, Polsky D. Association of melanoma and neurocutaneous melanocytosis with large congenital melanocytic naevi - results from the NYU - LCMN registry. British Journal of Dermatology 2005; 152(3):512-7. doi.org/10.1111/j.1365-2133.2005.06316.x.
6. Soong LC, Bencivenga A, Fiorillo L. Neonatal Curettage of Large to Giant Congenital Melanocytic Nevi Under Local Anesthetic: A Case Series With Long-Term Follow Up. Journal of cutaneous medicine and surgery 2022; 26(2):149-155.
7. Kovalyshyn I, Braun R, Marghoob A. Congenital melanocytic naevi. Australas J Dermatol 2009; 50:231-240.

INTERNATIONAL JOURNAL
of PEDIATRIC DERMATOLOGY

Special Issue, 2025
ISSN 3035-1006 online

Narrative Review

The Three Most Important Things to Tell Parents of a Child With Café-au-lait Macules

Laura Ciulli[1]

[1]*Pediatrician, ASST Valtellina e Alto Lario, Sondrio, Italy*

KEYWORDS

Café-au-lait macules
CALMs
Hypermelanosis
Neurofibromatosis type 1
Legius syndrome
McCune Albright Syndrome

ABSTRACT

Café-au-lait macules are common pigmented lesions, either congenital or acquired during the first years of life, and should not necessarily be regarded as indicators of an underlying syndromic condition. Their main distinguishing features from other hyperpigmented lesions are described, and all syndromic disorders associated with the presence of café-au-lait macules are reviewed.

CORRESPONDING AUTHOR

Laura Ciulli,
Pediatrician
ASST Valtellina e Alto Lario,
Sondrio, Italy

e-mail: laura.ciulli@tiscali.it

Copyright 2025 © by World Health Academy Publishing House
This publication and/or article is for individual use only and may not be further reproduced without written permission from the copyright holder.
Unauthorized reproduction may result in financial and other penalties
DISCLOSURE: ALL AUTHORS REPORT NO CONFLICTS OF INTEREST RELEVANT TO THIS ARTICLE.

Introduction

The macula belongs to the group of elementary lesions (macula, papule, nodule, vesicle, pustule, pompho) and differs from the blotch/spot only in size (macula > 1 cm, spot < 1 cm); it is a flat, circumscribed non-palpable lesion with sharp, regular margins, round, oval and sometimes irregular in shape.

The normal colour of the skin is given by the chromatic superimposition of four pigments: melanin brown, carotene yellow, oxyhaemoglobin bright red and reduced haemoglobin red-blue.

Café-au-lait macules (CALMs)

CALMs belong to the group of hypermelanosis or genetic epidermal melanodermias, they are "hyperchromic lesions" due to the accumulation or altered distribution of melanin with unchanged numbers of melanocytes.

Melanin is produced by melanocytes (dendritic cells located at the dermoepidermal junction) and transferred in granules (melanosomes) to keratinocytes.

The colour shade of skin lesions of melanocytic origin will be a function of the depth of melanin deposition: superficial layers of the epidermis (black), dermal-epidermal junction (dark to light brown), superficial dermis (slate grey blue), deep dermis (electric blue).

Priority need for a differential diagnosis between coffee-milk spots and other hyperchromic spots, such as Hyperchromic Nevus due to a mutation occurring during foetal life, homogeneous brown colouring, generally single with variable extension (a few centimetres to many decimetres up to affecting a haemithorax or limb with blaskoid distribution) with indented margins and irregular outline; or with Ephelides multiple macules < 5 mm, round or oval, irregular borders, localised on the face or other photo-exposed sites, frequent in children with light-coloured hair and eyes.

If observed in young children, a differential diagnosis with Congenital Melanocytic Nevus (NMC) at onset must be made. Dermoscopy (globular or reticular pattern for increased melanocyte number that is absent in CALMs) and Wood's light (CALMS increased melanin with Wood's ++ finding) can be useful for diagnosis.

CALMs are homogeneous light-brown flat lesions, sometimes almost invisibility, wich may be present at birth or in the first years of life (Fig.1 a, b). We need not worry if less than three are present in a normal child in the absence of a family history of genetic disorders (1). About one third of healthy school-age children have at least one CALM (2).

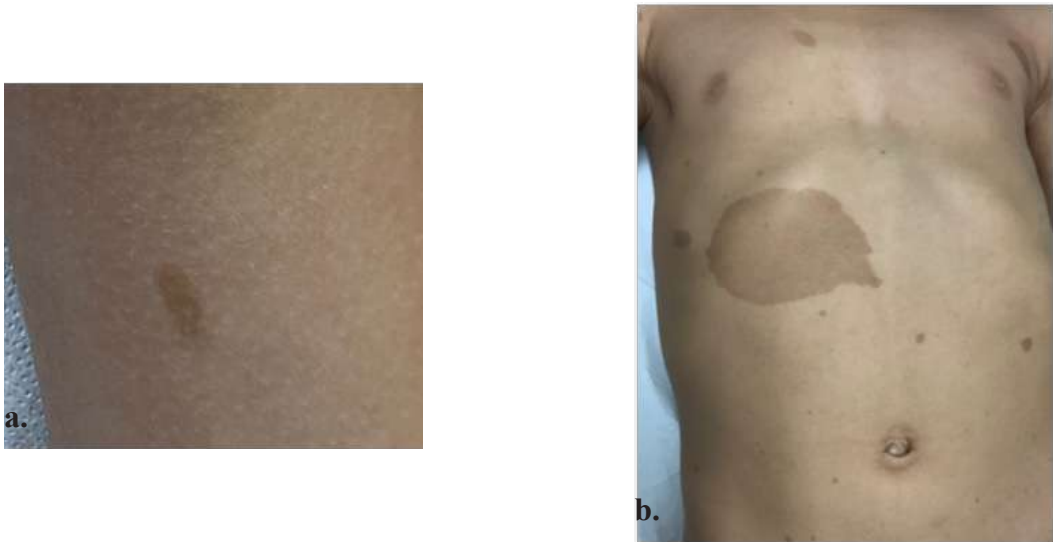

Fig. 1. *Presence of single (**a**) and multiple (**b**) café-au-lait macules on the skin.*

It is necessary to investigate when we have ≥6 patches >5 mm (before the age of 5) familiarity for genetic disorders (check parents), neurological signs, skin nodules, axillary or inguinal freckles, CALMs atypical in shape or distribution (3).

Note that 'typical' CALMs (homogeneous pigmentation and well-defined borders) are better predictors of underlying genetic disease than 'atypical' CALMs (irregular pigmentation and poorly defined borders).

CALMs are a suggestive but not exclusive sign of Neurofibromatosis type 1 (NF-1) and their presence generates anxiety and concern also as a consequence of increasing access to the web as a source of information.

In a minority of cases, certain pathologies may be associated with them, as shown in Table I.

Table I. *Syndromes with CALMs.*

Syndromes	Associated Anomalies
Multiple Familial CALMs	None. Only CALMs and freckling with no other signs of NF1
Legius Syndrome (NF1-like)	None. Only CALMs and freckling with no other signs of NF1
NF1 e and 2	Lisch nodules, optic nerve gliomas, skeletal anomalies, benign and malignant neoplasms
Watson Syndrome	Pulmonic stenosis, intellectual disability, short stature, relative macrocephaly, Lisch nodules, neurofibromas
McCune-Albright Syndrome	Fibrous dysplasia of the bone, precocious puberty (several endocrinopathies)
LEOPARD Syndrome	Congenital heart anomalies, pulmonic stenosis, abnormal genitalia, growth retardation, skeletal anomalies
Westerhof-Beemer-Cormane Syndrome	Hypopigmented skin patches, Intellectual disability, hort stsature, skeletal and sometimes neurological abnormalities
Tuberous Sclerosis	Hypopigmented macules, facial angiofibromas, periungual fibromas, cortical tubers (neurological disorders)
Bloom Syndrome	Short stature, photosensitivity and predisposition to tumor development
Ataxia-telangiectasia Syndrome	Cerebellar ataxia (lack of coordination), telangiectasias (dilated blood vessels), immunodeficiency, and an increased risk of cancer
Fanconi anemia (bone marrow aplasia**)**	Skeletal anomalies, microcephaly, endocrine, renal and genitourinary system abnormalities. predisposition to the development of leukemia and tumors

Neurofibromatosis type 1

Von Recklinghausen disease is part of a heterogeneous group of neuroectodermal diseases. It has an incidence of 1:2500-1:3000; equal incidence between the sexes, mutation in an oncosuppressor gene (17 q 11.2). The diagnosis is based on the presence of at least 2 of the criteria encoded by the National Institutes of Health (NIH). Full penetrance is age dependent, expressivity variable and the course unpredictable.

CALMs are the first and earliest manifestation of NF-1(<95%), sometimes detectable at birth, usually appearing by 2 years of age; followed by Freckling or axillary or inguinal freckles (at school age), Lisch iris nodules and cutaneous Neurofibromas (pre-puberty).

A presentation of at least 6 CALMs (diameter greater than 5 mm before puberty and 15 mm after puberty) fulfils one of the NIH clinical diagnostic criteria for both NF1 and Legius syndrome (NF1- like) (4).

Although there are no guidelines for how long to monitor patients with less than 6 CALMs, children older than 29 months with less than 6 CALMs have a 0.9% risk of developing NF1 and almost all patients with NF1 will meet the diagnostic criteria by the age of 8 years (5).

CALMs of NF1 have a homogeneous light brown to dark brown colour, regular margins, rounded or oval (typical CALMs such as "*California Coast*"), varying diameter from 0.5 to 50 cm, growing proportionally to the affected body segment those present in the first year of life, then smaller ones will appear with random distribution.

Legius syndrome (NF1- like)

Is rare and transmitted in an autosomal dominant manner, the mutation is in the SPRED1 gene on chromosome 15, > 6 CALMs (> 80%) + intertriginous freckles (50%) no typical NF1 manifestations (neurofibromas, Lisch nodules, optic gliomas, nor neoplastic and bone complications), macrocephaly and neurobehavioral disorders may be present (6).

McCune Albright Syndrome (SMA)

Is characterised by large CALMs with jagged edges like the 'Maine Coast' that do not cross the midline and follow the Blaschko lines. It has a prevalence of 1:30.000 and is due to a mutation in the GNAS gene. The clinical signs are age-dependent: CALMs (almost always present at birth), precocious puberty (50% probability in females within 4 years) and bone dysplasia (50% probability of onset within 8 years).

Café-Au-Lait Macules (CALMs) do not have an evolutionary character and therefore treatment for aesthetic improvement only with Q-switched laser can be proposed.

Practical course for the paediatrician in the face of CALMs:

a. Observe number, size and shape;
b. Complete examination for associated neurological or cutaneous signs;
c. Accurate family history;
d. Early classification of atypical cases, if suspected send to centre;
e. Do not alarm families unnecessarily (early diagnosis is of little use);
f. The key to management is monitoring over time.

The three most important things to tell parents

1. CALMs are innocent and very frequent lesions; 1/3 of healthy children have ≥ 1; If they create discomfort in the future, they can be removed by laser.
2. It is not justified to think of NF1 when the typical ones are less than six.
3. In the vast majority of cases, the involvement is exclusively cutaneous and life can be completely normal. Complications are rare and mostly treatable.

References

1. Lalor L, Davies OMT, Basel D, Siegel DH. Café au lait spots: when and how to pursue their genetic origins. Clin Dermatol. 2020;38(4):421-431.
2. Burwell RG, James NJ, Johnston DI. Café-au-lait spots in schoolchildren. Arch Dis Child. 1982;57(8):631-2.
3. Albaghdadi M, Berseneva M, Pennal A, et al. Value of a café-au-lait macules screening clinic: experience from the hospital for sick chil dren in Toronto. Pediatr Dermatol. 2022;39(2):205-210.
4. Legius E, Messiaen L, Wolkenstein P, et al. Revised diagnostic criteria for neurofibromatosis type 1 and Legius syndrome: an international consensus recommendation. Genet Med. 2021;23(8):1506-1513.
5. Ben-Shachar S, Dubov T, Toledano-Alhadef H, et al. Predicting neuro fibromatosis type 1 risk among children with isolated café-au-lait macules. J Am Acad Dermatol. 2017;76(6):1077-1083.e3.
6. Benelli E, Berti I. Dura Legius sed Legius. Physician and Child electronic pages 2015;18(5).

INTERNATIONAL JOURNAL
of PEDIATRIC DERMATOLOGY

Special Issue, 2025
ISSN 3035-1006 online

Narrative Review

The Three Most Important Things to Tell the Parents of a Child with Atopic Dermatitis

Francesco Mazzotta[1,2]

[1]Dermatologist, Pediatric Dermatology Outpatients Unit, Barletta, Italy;
[2] ASL Barletta, Andria, Trani, Italy

KEYWORDS

Atopic dermatitits,
Therapeutic education,
Comunication,
Management

ABSTRACT

Atopic dermatitis is a highly frequent disease in the pediatric population, with an estimated prevalence of approximately 20%. Parents are often confused and they may compulsively consult nutritionists, pharmacists, immunologists, or homeopaths in search of new treatments. Given the fundamental importance of therapeutic education in achieving effective clinical outcomes, this paper outlines the essential information that should be communicated to parents regarding the diagnosis, treatment, and follow-up of the disease.

CORRESPONDING AUTHOR

Francesco Mazzotta
Dermatologist, Pediatric Dermatology Outpatients Unit, Barletta,
ASL Barletta, Andria, Trani, Italy

f.mazzotta635@gmail.com

Copyright 2025 © by World Health Academy Publishing House
This publication and/or article is for individual use only and may not be further reproduced without written permission from the copyright holder.
Unauthorized reproduction may result in financial and other penalties
DISCLOSURE: ALL AUTHORS REPORT NO CONFLICTS OF INTEREST RELEVANT TO THIS ARTICLE.

Introduction

Atopic dermatitis (AD) is a chronic inflammatory skin disease that usually appears in childhood. Its prevalence varies with age, with averages around 20%, but peaks can reach up to 30% during the first year of life (1).

Most cases encountered by a pediatrician are mild forms, but in moderate-to-severe cases, atopic dermatitis is classified as the inflammatory skin disease with the highest disability-adjusted life year (DALY) - the number of years lost due to disease-related disability (2). This is also because it's now well-established that the disease has flare-ups even after puberty, extending into adulthood and old age (3).

In recent decades, we've seen a clear increase in the prevalence of atopic dermatitis, likely due to several factors, including environmental pollution. There is significant evidence that PM2.5 particulate matter can alter the skin barrier - one of the key pathogenic factors of AD (4). It's also known that most dermatological consultations for AD involve patients living in areas with high concentrations of volatile organic compounds (e.g., 1,3,5-trimethylbenzene, methylcyclohexane) (5).

The clear upward trend in atopic dermatitis cases in developed countries has spurred economic interest in researching new treatments for this chronic, relapsing condition.

Thanks to "translational medicine", new drugs targeting the pathogenesis of AD have been developed, achieving excellent results in moderate-to-severe cases that do not respond to topical therapies and were previously treated with immunosuppressants (6).

At the same time, the prospect of economic gain has fueled the proliferation of countless so-called "miraculous" alternative therapies, which have found powerful resonance on the web.

Parents are often confused and, faced with flare-ups, they may compulsively consult nutritionists, pharmacists, immunologists, or homeopaths in search of new treatments they've heard about - or worse, fall into the trap of online "miracle cures," spending significant amounts of money to no avail (7).

All of this could be avoided by establishing a virtuous circuit in which the pediatrician serves as a central point of reference, working closely with pediatric dermatologists and pediatric allergists (Fig.1).

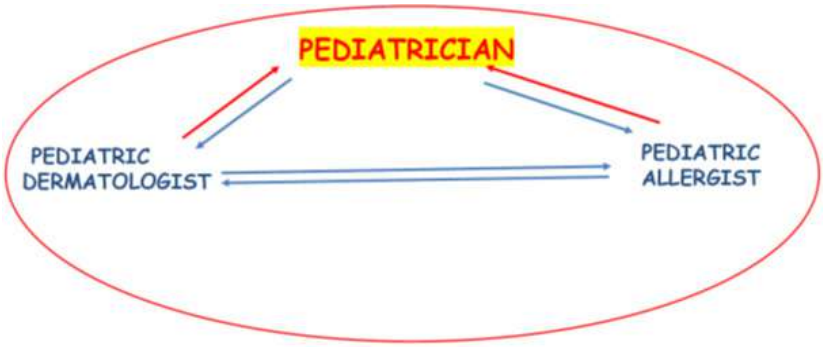

Fig. 1. *The virtuos circuit.*

In this current chaotic context, marked by the emergence of numerous new therapies, it is essential to remember that therapeutic education is the foundation for successful outcomes in any chronic condition, and is included in all treatment guidelines for atopic dermatitis.

To ensure proper educational communication, it would be useful to convey three practical tips to parents and adolescents - to explain what AD is, what the therapeutic goals are, and which behavioral norms should be followed.

Once a definitive diagnosis of atopic dermatitis has been made, communication can proceed as follows:

1)*Communicating the Diagnosis*

Atopic dermatitis is a chronic, relapsing inflammatory skin disease that is very common in childhood. The italian healthcare system allows us to treat moderate and severe forms free of charge, including with costly innovative drugs. for mild forms, specific products need to be purchased and used properly to avoid complications.

2) *Communicating the Therapy*

For Parents of Children Aged 0-9:

Treatment requires commitment, ideally with a designated "care manager" to coordinate hygiene and topycal/systemic treatments. scheduled follow-up visits must be respected because ad is a chronic disease, even during remission, minimal management may be necessary.

Treatment consistently improves the patient's quality of life and that of the entire family.

Prescriptions for your child are not universal. Sharing and comparing them in online chats with other patients is pointless.

For Adolescents Aged 12-16 it's necessary to add:

You are the main actor in managing this treatable skin disease. follow hygiene rules, ask your parents to help you carry out the treatment correctly and report any skin issues, especially in areas covered by clothes.

Keep track of when your cleansers or emollient creams are running low, and use your smartphone to schedule follow-up visits, reminding your parents to accompany you.

3) *Communicating Follow-up Behavior*

Any new developments must be reported to your pediatrician, who will decide in agreement with your dermatologist or allergist wether to perform allergy test or clinical instrumental investigation to look for associated conditions.

If you are an internet enthusiast, visit only official scientific society websites, and always consult your pediatrician before making decisions.

Conclusions

These three pieces of advice come from my 35 years of experience in treating atopic dermatitis. They could be valid in all countries with advanced national healthcare systems. Unfortunately, for atopic dermatitis, access to care remains limited and unequal in many nations, as reported by the International Society for Atopic Dermatitis in 2023 (8).

References

1. Silverberg JI, Barbarot S, Gadkari A, Simpson EL, Weidinger S, Mina-Osorio P, et al. Atopic dermatitis in the pediatric population: a cross-sectional, international epidemiologic study. Ann Allergy Asthma Immunol. 2021;126, 417-428.e2.

2. Laughter MR, Maymone MBC, Mashayekhi S, et al. The global burden of atopic dermatitis: lessons from the Global Burden of Disease Study 1990-2017. Br J Dermatol. 2021; 184:304-9.

3. Maurelli M, Chiricozzi A, Peris K, Gisondi P, Girolomoni G. Atopic Dermatitis in the Elderly Population. Acta Derm Venereol. 2023;103:adv13363. doi: 10.2340/actadv.v103.13363.

4. Kim BE, Kim J, Goleva E, Berdyshev E, Lee J, Vang KA, Lee UH, Han S, Leung S, Hall CF, Kim NR, Bronova I, Lee EJ, Yang HR, Leung DY, Ahn K. Particulate matter causes skin barrier dysfunction. JCI Insight. 2021; 6(5):e145185. doi: 10.1172/jci.insight.145185.

5. Tseng HW. Positive effect of exposure to ambient air volatile organic compounds on clinic visits for atopic dermatitis. Asian Pac J Allergy Immunol. 2024. doi: 10.12932/AP-250224-1796.

6. Facheris P, Jeffery J, Del Duca E, Guttman-Yassky E. The translational revolution in atopic dermatitis: the paradigm shift from pathogenesis to treatment. Cell Mol Immunol. 2023; 20(5):448-474. doi: 10.1038/s41423-023-00992-4.

7. O'Connor C, Murphy M. Scratching the surface: a review of online misinformation and conspiracy theories in atopic dermatitis. Clin Exp Dermatol. 2021; 46(8):1545-1547. doi: 10.1111/ced.14679. 33864398.

8. Faye O, Flohr C, Kabashima K, Ma L, Paller AS, Rapelanoro FR, et al. Atopic dermatitis: A global health perspective. J Eur Acad Dermatol Venereol. 2024; 38:801–811. https://doi.org/10.1111/jdv.19723.

INTERNATIONAL JOURNAL
of PEDIATRIC DERMATOLOGY

Special Issue, 2025
ISSN 3035-1006 online

Narrative Review

The Three Most Important Things to Tell Parents of a Newborn/Infant with Scabies

Giuseppe Ruggiero[1]

[1]*Pediatrician, G. Marconi University, Rome, Italy*

KEYWORDS

Scabies,
Itching dermatitis,
Permethrin,
Ivermectin

ABSTRACT

Cases of pediatric scabies are increasing in many countries around the world. The author outlines the main clinical criteria for diagnosis and the most characteristic dermoscopic findings. Finally, he discusses treatment options and the reported increase in cases resistant to topical permethrin therapy.

CORRESPONDING AUTHOR

Giuseppe Ruggiero
Pediatrician,
Università G. Marconi,
Rome, Italy

doc.rug.giu@gmail.com

Copyright 2025 © by World Health Academy Publishing House
This publication and/or article is for individual use only and may not be further reproduced without written permission from the copyright holder.
Unauthorized reproduction may result in financial and other penalties
DISCLOSURE: ALL AUTHORS REPORT NO CONFLICTS OF INTEREST RELEVANT TO THIS ARTICLE.

Introduction

Scabies is an ectoparasitic skin disease caused by Sarcoptes scabiei varietas hominis, transmitted through direct skin-to-skin contact. Female mites, which are slightly larger (0.3 - 0.5 mm) than males, burrow into the stratum corneum and lay eggs (1). The eggs hatch into larvae within 3 - 4 days, but less than 1% of them develop into adult mites. The female mite's life cycle spans 4 to 6 weeks. Outside the human host, mites can survive for up to 36 hours at room temperature. Scabies is currently a widespread global problem, and the epidemic shows no signs of decline. In developing countries, where healthcare is inadequate and medications are expensive, the disease remains persistent (1, 2).

Clinical manifestations

The clinical symptoms of scabies typically appear about one month after initial infestation. The most prominent symptom is itching, which becomes especially intense at night (Fig. 1). Clinical manifestations include: burrows, erythematous papules, excoriations, nodules (Fig. 2), vesicopustular or bullous lesions, eczema, and secondary bacterial infection (Fig. 3).

Burrows are most commonly found on the hands, particularly between the fingers and on the wrists. Other predilection sites include the soles of the feet, palms, axillae, male genitalia, and the areolae in women. In infants, burrows can also be observed on the scalp, especially in the postauricular folds. Sometimes, there may be nonspecific erythematous papules, extensive excoriations, or nodules, making it difficult to differentiate from other dermatoses (Fig. 4).

Fig. 1. *Itching and scratching.*

Fig. 2. *Burrows, erythematous papules,excoriations and nodules.*

Fig. 3. *Vesicopustular or bullous lesions, eczema, and secondary bacterial infection.*

Fig. 4. *The 'jet with trail' sign and extensive excoriations.*

Diagnosis

Scabies should be suspected in infants or children with recent-onset generalized itching and the characteristic rash. Other family members are usually, but not always, affected.

A detailed history of scabies or contact with scabies should be specifically elicited, along with any reports of itching or itchy skin lesions in family members.

Recent diagnoses of eczema or insect bites in relatives or close personal contacts must be critically evaluated.

The 2020 International Alliance for the Control of Scabies Consensus Criteria criteria define three diagnostic levels representing varying degrees of certainty (3):

- Confirmed Scabies (Level A): The most specific, requiring direct visualization of the mite or its products;
- Clinical Scabies (Level B);
- Suspected Scabies (Level C);

Both based on clinical assessment of signs and symptoms.

Confirmed scabies (Level A) involves the identification of mite products through:

1. Skin scraping and microscopic examination (A1);
2. Non-invasive high-magnification devices such as videodermoscopy and reflectance confocal microscopy (A2);
3. Dermoscopy (A3), which allows visualization of the mite's burrow and the triangular brown spot corresponding to the female mite's head. The burrow is clearly visible as a thin white line known as the 'jet with trail' sign (Fig. 5).

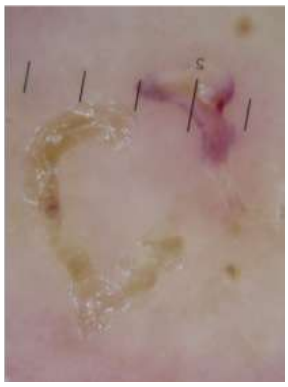

Fig. 5. *The 'jet with trail' sign and extensive excoriations.*

Therapy

Topical Therapy

- Permethrin 5% cream or lotion has long been considered the gold standard treatment for scabies (4). However, recent studies indicate increasing mite resistance to permethrin. Some literature suggests this perceived resistance may be due to improper application rather than genuine resistance (5). Permethrin cream is typically applied at night to the entire body from the neck down, including the scalp and face (in children), left on for 8-14 hours, and then rinsed off. Treatment is repeated for three consecutive nights and again one week later to ensure complete eradication of mites and eggs.Permethrin acts by disrupting sodium transport across nerve cell membranes in invertebrates, interfering with neurotransmission. Less than 2% of permethrin applied to the skin is absorbed and is rapidly eliminated from the body.
- Benzyl benzoate is a good alternative, with effective concentrations of 10 - 15% in children and 20 - 25% in adults. Benzyl benzoate is typically applied at night to the entire body from the neck down, including the scalp and face (in children). It should be applied once daily for 3 to 4 consecutive days, left in place for 12 to 24 hours before washing off. A second course is usually repeated after 7 days. It acts by immobilizing and inhibiting mite reproduction but may cause more skin irritation.
- Sulfur-based preparations (3 - 10% compounded, 12.5% commercial) are commonly used in Turkey for topical scabies treatment (6). A 17% sulfur ointment has been successfully used in Italy for 22 pediatric patients aged 4 months to 17 years, with 100% resolution and no side effects reported (7).

Systemic Therapy

- Ivermectin (0.2 mg/kg orally, taken once, and then repeated after 7 to 14 days) blocks GABA-mediated neurotransmission in parasites but does not readily cross the blood-brain barrier in most mammals, including humans. Its serum half-life is 18 hours and it is excreted renally after hepatic metabolism. Ivermectin is not approved for children under 5 years, pregnant or lactating women, or those under 15 kg (8). A recent retrospective French study on 170 children under 15 kg reported 85% effectiveness with only mild side effects, such as eczema and gastrointestinal discomfort, in 9 patients (9).

Environmental Treatment

-Thorough disinfection of the environment, including bed linens, towels, and clothing used in the past 2 days, is necessary.
- Bed linens and nightwear should be changed and washed at 60°C every morning during the treatment period.
- All clothing worn in the past 2 days should also be washed at 60°C.
- Non-washable items can be isolated in plastic bags for 1 week or kept at temperatures below 10°C (refrigerator or outdoors in winter).
- Steam cleaners with high-temperature output are recommended for treating mattresses, sofas, chairs, and floors.

Causes of Treatment Failure

- Miscommunication between physician and patient
- Poor treatment compliance (e.g., improper use of medications)
- Immediate reinfestation (beware of asymptomatic carriers)
- Negligence in contact tracing and prevention procedures
- Possible resistance of Sarcoptes to the medication used?

The Three Most Important Things to Tell Parents of a Newborn/Infant with Scabies

1. If your child has unexplained itching, consult your pediatrician.
2. Administer the treatment to your child correctly, following the instructions precisely.
3. Ensure all contacts of the child are treated as well.

References

1. Harper's Textbook of Pediatric Dermatology, Fourth Edition. Edited by Peter Hoeger, Veronica Kinsler and Albert Yan. 2020.
2. Walton SF, Currie BJ. Problems in diagnosing scabies, a global disease in human and animal populations. Clin Microbiol Rev. 2007; 20:268–279.
3. Engelman D et al. The 2020 International Alliance for the Control of Scabies Consensus Criteria for the Diagnosis of Scabies. Brit J Dermatol.2020; 183(5):808-820.
4. Soner U et al. Clinical practice guidelines for the diagnosis and treatment of scabies. Int J Dermatol. 2024; 63(12):1642-1656.
5. Yurekli A. Is there a really resistance to scabies treatment with permethrin? In vitro killing activity of permethrin on Sarcoptes scabiei from patients with resistant scabies. Derm Ther. 2022; 35(3):e15260.
6. Uzun S et al. Clinical practice guidelines for the diagnosis and treatment of scabies. Int J Dermatol. 2024; 63(12):1642-1656.
7. Baffa ME et al. Sulfur 17% ointment for topical treatment of scabies in children: old but gold. Int J Dermatol. 2024; 63(1):e19-e20.
8. Becourt C, Marguet C, Balguerie X, Joly P. Treatment of scabies with oral ivermectin in 15 infants: a retrospective study on tolerance and efficacy. Br J Dermatol. 2013; 169(4):931-3.
9. Levy M et al. Ivermectin safety in infants and chil-

dren under 15 kg treated for scabies: a multicentric observational study. Br J Dermatol. 2020; 182(4):1003-1006.

INTERNATIONAL JOURNAL
of PEDIATRIC DERMATOLOGY

Special Issue, 2025
ISSN 3035-1006 online

Narrative Review

The Three Most Important Messages for Parents of a Child with Facial Infantile Hemangioma

Andrea Diociaiuti[1]

[1]*Dermatology Unit and Genodermatosis Research Unit, Translational Paediatrics and Clinical Genetics Research Division, Bambino Gesù Children's Hospital IRCCS, Rome, Italy*

KEYWORDS

Infantile Hemangioma,
Vascular tumors,
Beta-blocker,
Propranolol

ABSTRACT

Infantile hemangioma (IH) is the most common vascular tumor affecting infants. The most IH lesions follow a benign and self-limited course. Facial IHs are especially concerning because of their potential functional impairment and psychosocial impact. The author illustrates the main useful information to help families understand the nature of this injury, its progression over time and the therapeutic management options.

CORRESPONDING AUTHOR

Andrea Diociaiuti,
Dermatologist,
Dermatology Unit and Genodermatosis Research Unit, Translational Paediatrics and Clinical Genetics Research Division, Bambino Gesù Children's Hospital IRCCS, Rome, Italy

andrea.diociaiuti@opbg.net

Copyright 2025 © by World Health Academy Publishing House
This publication and/or article is for individual use only and may not be further reproduced without written permission from the copyright holder.
Unauthorized reproduction may result in financial and other penalties
DISCLOSURE: ALL AUTHORS REPORT NO CONFLICTS OF INTEREST RELEVANT TO THIS ARTICLE.

Introduction

Infantile hemangioma (IH) is the most common vascular tumor affecting infants, occurring in approximately 4% of children. It predominantly affects females, with a female-to-male ratio near 3:1. While most IH lesions follow a benign, self-limited course, about 12% require specialized evaluation and treatment due to risk of complications. Facial IHs are especially concerning because of their visible location, potential functional impairment, and psychosocial impact. Clear, compassionate communication with parents from diagnosis onward is crucial to help families understand the condition's nature, expected course, and management options.

IHs typically develop in three phases. The initial proliferative phase begins shortly after birth and is characterized by rapid endothelial cell growth and tumor enlargement. This phase often raises alarm among parents because of the fast and sometimes dramatic increase in lesion size, especially when on the face. The subsequent plateau phase involves stabilization of growth. Finally, the involutional phase entails gradual regression of the lesion over months to years. It is important for clinicians to emphasize the usually benign nature of IH and the expectation that most lesions will shrink and become less noticeable without intervention, which can reassure parents and reduce anxiety.

Clinical presentation

However, prognosis is not determined solely by tumor biology but largely depends on lesion location, size, and number. Hemangiomas near vital facial structures such as the eyes, nose, lips, and airway can cause functional problems (Fig. 1). For example, periocular hemangiomas may interfere with vision and cause amblyopia. Airway hemangiomas—often seen in PHACE syndrome—may obstruct breathing and necessitate urgent treatment. PHACE syndrome, a complex disorder involving posterior fossa malformations, arterial anomalies, cardiac defects, and eye abnormalities, is frequently associated with subglottic hemangiomas that can compromise the airway and require close monitoring and intervention (1).

Fig. 1. *Infant affected by infantile haemangioma of the upper lip, which deforms the lip and interferes with breastfeeding.*

Complications

Ulceration is a common and troubling complication of IH, most frequently occurring during the proliferative phase but possible in all stages. Ulcerated hemangiomas cause significant pain, risk infection, bleeding, and distress to both infant and caregivers (Fig. 2). Management requires careful wound care using advanced dressings such as silicone or hydrocolloid materials that protect the lesion and promote healing. Parents should receive detailed instructions on wound care to minimize complications and discomfort (2).

Bleeding from ulcerated IH can often be controlled initially with pressure dressings. Topical tranexamic acid may assist in controlling hemorrhage. While rare, persistent or severe bleeding may require embolization or surgical removal (5). Infections complicate up to 43% of ulcerated hemangiomas. Superficial infections typically respond to topical antibiotics, but systemic antibiotics are warranted if deeper or spreading infection is suspected (5).

Fig. 2. *Infant affected by infantile haemangioma of the right ear. The lesion is ulcerated, is painful and deforms the pavilion.*

Treatment

The introduction of propranolol revolutionized IH treatment. This non-selective beta-blocker rapidly reduces tumor size and vascularity through vasoconstriction, inhibition of angiogenesis, and induction of endothelial cell apoptosis. Propranolol is now the first-line therapy for complicated IH, including those causing functional impairment or ulceration. Its efficacy and safety are supported by multiple studies and large patient cohorts (4). Treatment initiation requires educating parents on potential side effects such as bradycardia, hypotension, hypoglycemia, and bronchospasm. Careful monitoring during dose escalation is critical to ensure safety and optimize outcomes.

Adjunctive pulsed dye laser (PDL) therapy can accelerate healing of ulcerated hemangiomas, reduce pain, and improve residual cosmetic appearance. Studies demonstrate that combining propranolol with laser therapy results in superior clinical outcomes, with over 90% of patients showing improvement after an average of two laser sessions (4).

Terapeutic education

Therapeutic education is fundamental for successful IH management. Clear communication, empathetic support, and active parental involvement in decision-making foster compliance and reduce anxiety. Providing written materials and nursing support for wound care and medication administration can empower families to confidently manage their child's condition at home. Because facial IH can cause visible changes affecting social interactions and self-esteem, multidisciplinary care involving dermatology, pediatrics, surgery, and psychology is often beneficial to address medical and emotional needs comprehensively.

Conclusion

In conclusion, managing facial infantile hemangiomas requires a comprehensive approach combining expert medical care, vigilant monitoring, and effective family education. Clinicians must convey the natural history of IH, address complications such as airway obstruction and ulceration, and explain evolving treatments like propranolol and laser therapy. Supporting families through clear communication and multidisciplinary care optimizes both medical and psychosocial outcomes for children with facial IH.

References

1. Durr ML, Meyer AK, Huoh KC, Frieden IJ, Rosbe KW. Airway hemangiomas in PHACE syndrome. Laryngoscope. 2012.
2. Chamlin SL, Haggstrom AN, Drolet BA, Baselga E, Frieden IJ, Garzon MC, et al. Multicenter prospective study of ulcerated hemangiomas. J Pediatr. 2007; 151:684-9.
3. Lapidoth M, Ben-Amitai D, Bhandarkar S, Fried L, Arbiser JL. Efficacy of topical application of eosin for ulcerated hemangiomas. J Am Acad Dermatol. 2009; 60(2):350-1.
4. Reddy KK, Blei F, Brauer JA, Waner M. Infantile hemangiomas treated with a combination of propranolol and pulsed dye laser. Lasers Surg Med. 2012; 44 Suppl. 24:3.
5. McCuaig CC, Cohen L, Powell J, Hatami A et al. Therapy of ulcerated hemangiomas. J Cutan Med Surg. 2013; 17(4):233-42.

INTERNATIONAL JOURNAL
of PEDIATRIC DERMATOLOGY

Special Issue, 2025
ISSN 3035-1006 online

Narrative Review

How to Manage a Severe Urticaria

Francesca Mori[1]

[1]*Allergy Unit, Meyer Children's Hospital IRCCS, Florence, Italy*

KEYWORDS

Chronic urticaria,
CSU,
Hives,
Angioedema

ABSTRACT

Chronic spontaneous urticaria (CSU) is a condition characterized by the recurrent appearance of wheals (hives) and/or angioedema lasting for more than six weeks without an identifiable trigger. It is often difficult to treat but recent advances in the understanding of pathophysiology allows for the adoption of more personalized treatments (1). The author reports the most recent findings regarding diagnosis, monitoring and therapeutic approach (2).

CORRESPONDING AUTHOR

Francesca Mori,
Pediatrician,
Allergy Unit,
Meyer Children's Hospital IRCCS,
Florence, Italy

e-mail: f.mori@meyer.it

Copyright 2025 © by World Health Academy Publishing House
This publication and/or article is for individual use only and may not be further reproduced without written permission from the copyright holder.
Unauthorized reproduction may result in financial and other penalties
DISCLOSURE: ALL AUTHORS REPORT NO CONFLICTS OF INTEREST RELEVANT TO THIS ARTICLE.

Definition and epidemiology

Urticaria is defined by transient, itchy, raised skin lesions (wheals) that typically last less than 24 hours and are often associated with a burning sensation. Angioedema, which involves swelling of deeper skin layers and mucous membranes, may accompany chronic urticaria (40-50% of cases) or occur independently (10% of cases) (1).

In pediatric populations, the prevalence of CSU ranges from 0.7% in Europe to 1.8% in Korea. Prognosis varies: remission occurs in about 10–32% of cases after one year, and up to 72% after five years (1).

Pathophysiology and classification

Chronic Urticaria is classified into:

• **Spontaneous forms** (idiopathic, allergic, or pseudo-allergic) representing 80% of cases.

• **Inducible forms** (triggered by physical stimuli like cold, heat, pressure, or sunlight) (Fig.1), representing 20% of cases.

Fig. 1. *Symptomatic dermatographism.*

CSU involves mast cell activation, which is driven by multiple pathways:

• IgE receptors (FcεRI)
• MRGPRX2 receptors
• Complement system components (e.g. C5a)
• Cytokine and protease-activated receptors

Two main CSU endotypes are discussed:

• **Type I (autoallergic)**: mediated by IgE autoantibodies (IgE anti TPO, IgE anti Il-24, IgE anti dsDNA);
• **Type IIb (autoimmune)**: characterized by IgG autoantibodies against IgE or its receptor (3).

Phenotypes

Allergic Type I CSU affects 30-40% of children with CSU. They are characterized by the presence of high comorbid atopic diseases; high/normal total IgE; good response to omalizumab. This disease has usually a shorter duration when compared with autoimmune Type IIb CSU, it is not accompanied by angioedema and children are younger than those with autoimmune Type IIb CSU.

Autoimmune Type IIb CSU affects only 10% of children with CSU. They are characterized by the presence of high comorbid autoimmune diseases, low total IgE; poorer/slower response to omalizumab, longer duration of the disease which could be associated with angioedema. Children affected are older than those with allergic Type I CSU (4).

Diagnosis and monitoring

First-level diagnostic tests mostly include:
• Complete blood count, liver and kidney function, thyroid tests;
• Autoantibodies (e.g., anti-TPO), total IgE levels;
• Celiac disease screening.

There are not biomarkers to be used for diagnosing the correct phenotype. The cutoff value for IgG anti-TPO/total IgE ratio of 2.88 was defined for the detection of type IIb CSU on the basis of data from the PURIST study and it seems to be promising (5).

Disease activity is monitored using:
• **UAS7 (Urticaria Activity Score)**: a 7-day scoring system assessing daily hives and itching
• **UCT (Urticaria Control Test)**: a simple patient-reported tool for disease control assessment
CU-Q2oL is a questionnaire used to monitor quality of life.

Treatment approaches

Treatment follows a stepwise approach as recommended by international guidelines (EAACI/GA²LEN/WAO):
1. **Second-generation H1 antihistamines** (standard dose);
2. **Increased dose of antihistamines** (up to 4x);
3. **Biologic therapy**: **Omalizumab**, a monoclonal antibody targeting free IgE, is the only currently approved biologic for CSU.

Omalizumab is generally effective, with significant reductions in symptoms (UAS7) and improvement in quality of life. However, about 30% of patients are **non-responders**, and half may relapse after discontinuation. The treatment does not alter the long-term course of the disease but can be resumed with good efficacy (6-8).

Emerging therapies and research

Several new therapeutic strategies are under investigation, including:
• Next-generation anti-IgE therapies: Ligelizumab, UB-221;
• BTK inhibitors: Remibrutinib, Fenebrutinib – promising results in patients unresponsive to Omalizumab (9);
• Cytokine-targeting biologics: Dupilumab (IL-4/IL-13), Tezepelumab (TSLP), and others;
• Mast cell modulation strategies: JAK inhibitors, Siglec-8 agonists, and KIT inhibitors.

Conclusion

CSU is a heterogeneous and often difficult-to-treat condition. While many patients respond well to standard therapies, a significant subset remains refractory. Recent advances in the understanding of pathophysiological mechanisms are paving the way for more personalized, targeted treatments, which hold promise for improving outcomes in patients with severe, treatment-resistant CSU.

References

1. Zuberbier T, Abdul Latiff AH, Abuzakouk M, Aquilina S, Asero R, Baker D et al. The international EAACI/GA²LEN/EuroGuiDerm/APAAACI guideline for the definition, classification, diagnosis, and management of urticaria. Allergy. 2022; 77(3):734-766. doi: 10.1111/all.15090.
2. Ensina LF, Brandão LS, Melo ACDB, Antila M, Ben-Shoshan M, Solé D. Chronic urticaria treatment challenges in children. Rev Paul Pediatr. 2024; 20;43:e2024107. doi: 10.1590/1984-0462/2025/43/2024107.
3. Wong D, Waserman S, Sussman GL. Endotypes of chronic spontaneous urticaria and angioedema. J Allergy Clin Immunol. 2025; 156(1):17-23. doi: 10.1016/j.jaci.2025.04.004.
4. Kolkhir P, Bonnekoh H, Metz M, Maurer M. Chronic Spontaneous Urticaria: A Review. JAMA. 2024; 332(17):1464-1477. doi: 10.1001/jama.2024.15568.
5. Schoepke N, Asero R, Ellrich A, Ferrer M, Gimenez-Arnau A, E H Grattan C, et al. Biomarkers and clinical characteristics of autoimmune chronic spontaneous urticaria: Results of the PURIST Study. Allergy. 2019; 74(12):2427-2436. doi: 10.1111/all.13949.
6. Diamanti A, Tontini C, Bulfone-Paus S. Comparing novel treatments in chronic spontaneous urticaria: A critical appraisal of Bruton's tyrosine kinase inhibitors versus anti-cytokine biologics in clinical trials. Clin Transl Allergy. 2025; 15(4):e70053. doi: 10.1002/clt2.70053.
7. Kolkhir P, Fok JS, Kocatürk E, Li PH, Okas TL, Marcelino J, Metz M. Update on the Treatment of Chronic Spontaneous Urticaria. Drugs. 2025; 85(4):475-486. doi: 10.1007/s40265-025-02170-4. Epub 2025 Mar 12.
8. Podder I, Salman A, Asero R, Teresa Caballero M, Caffarelli C, De Las Vecillas L, et al. Biological drugs for the treatment of children with chronic spontaneous urticaria. Expert Rev Clin Immunol. 2024; 20(12):1427-1435. doi: 10.1080/1744666X.2024.2388689.
9. Metz M, Giménez-Arnau A, Hide M, Lebwohl M, Mosnaim G, Saini S, et al. REMIX-1 and REMIX-2 Investigators; REMIX-1 Investigators; REMIX-2 Investigators. Remibrutinib in Chronic Spontaneous Urticaria. N Engl J Med. 2025; 392(10):984-994. doi: 10.1056/NEJMoa2408792.

INTERNATIONAL JOURNAL
of PEDIATRIC DERMATOLOGY

Special Issue, 2025
ISSN 3035-1006 online

Narrative Review

Syphilis Disease and Teens: What Parents Need to Know and What They Need to Be Sure Their Teens Know

Sara Poggiali[1] and Roberta Bilenchi[2]

[1]*Azienda USL Toscana Sud Est; Siena, Italy;*
[2] *University of Siena, Siena, Italy*

KEYWORDS

Sexually transmitted diseases,
Syphilis,
Chancre,
Maculopapular rash,
VDRL,
Treponemal test

ABSTRACT

Sexually transmitted diseases (STDs) affect individuals of all ages, but they take an especially heavy toll on adolescents, who are particularly vulnerable due to both behavioral and biological factors. “Syphilis is one of the most significant sexually transmitted diseases. Although it is relatively uncommon in pediatric populations, it is essential for pediatricians to be able to recognize its clinical manifestations and to be familiar with the diagnostic tests required for accurate identification.

CORRESPONDING AUTHOR

Sara Poggiali MD PhD
Azienda USL Toscana Sud Est;
Siena, Italy

sara.poggiali@uslsudest.toscana.it

Copyright 2025 © by World Health Academy Publishing House
This publication and/or article is for individual use only and may not be further reproduced without written permission from the copyright holder.
Unauthorized reproduction may result in financial and other penalties
DISCLOSURE: ALL AUTHORS REPORT NO CONFLICTS OF INTEREST RELEVANT TO THIS ARTICLE.

Introduction

The COVID-19 pandemic had a detrimental impact on adolescent education and their interaction with peers and adults, secondary to the limitation of school and recreational activities, with repercussions on social and sexual life. Based on a study performed in the metropolitan city of Bologna, the most common source of sexual and reproductive health education was the web, followed by peers (friends). A total of 61.3% of 17-year-olds already had sexual intercourse, and 90% of 15-year-olds had experienced romantic or sexual attraction (1).

Sexually transmitted diseases (STDs) affect individuals of all ages but they take particularly heavy toll on young people (2). Adolescents are particularly vulnerable to STDs due to a combination of behavioral and biological factors and may face barriers to accessing sexaual health services. Among sexually active adolescents, those who do not use condoms consistently are men who have sex with men (MSM) (3).

In 2023 almost half of all reported cases of chlamydia, gonorrhea, and syphilis in the United States were among adolescents and young adults aged 15-24 (4).

Studies in Italy also indicate a concerning rise in STDs among adolescents and young adults. The most frequent genital infection reported among italian adolescents used to be vulvovaginal candidiasis (35% vs. 23.9% of adult people). HSV was found in 1.8% of teen-agers (vs. 0.6%) and when requested, Chlamydia trachomatis and mycoplasmas were found respectively in 16.6% (vs. 1.1%) and 50% (vs. 28%) of cases (3) A 2020-2021 surveillance system in Italy showed an 18% increase in STIs overall, with significant increases in Chlamydia, gonorrhea, and syphilis; MSM are at particular risk for syphilis infection (1).

With the rise in acquired syphilis infections, the incidence of congenital syphilis has also increased and according to CDC: 1 % increase in total syphilis (all stages and congenital syphilis combined) was reported in 2023(5).

People from racial and ethnic minority groups are experiencing the brunt of the newborn syphilis epidemic (5).

Syphilis

Venereal syphilis infection occurs after the spirochete Treponema pallidum subspecies directly penetrates the mucous membranes or enters through the breaches in the skin that result from sexual contact. The spirochete is long and flat, so can easily penetrate human tissue and vascular structures via an undulating, corkscrew movement. This early and widespread hematogenous dissemination explains the eventual widespread involvement of the disease. The outer membrane of the spirochete lacks both lipopolysaccharide and toll-like receptor 2 this helps the spirochete to evade detection by the innate immune system and help to explain the lack of systemic inflammation in primary syphilis.

In the first stage of infection there is usually a firm, round, painless sore (chancre) where the infection entered the body. Chancres are most often seen in men at the head of the penis, but can erupt anywhere that direct contact occurred (Fig. 1). Chancres have been reported in the vagina, cervix, in and around the rectum, in the mouth, and even on the fingers and neck. Treponema pallidum cannot be cultured. Diagnostic tests using dark-field microscopy or tests to detect T pallidum from lesion exudate are rarely and not easily performed. The chancre usually heals spontaneously without scarring within 4–6 weeks, but as it is painless it may go unnoticed and with treatment it will likely regress more quickly (within 2–3 days). Regional lymphadenopathy may or may not be present and may or may not be tender. Once opsonization occurs, spirochetes are more easily located and destroyed, causing a systemic inflammatory response and tissue damage that leads to the wide variety of clinical manifestations of secondary syphilis. Around 6–8 weeks after the healing of the chancre, secondary syphilis usually develops. The findings in secondary syphilis include generalized lymphadenopathy, a non-pruritic, maculopapular rash that often involves the palms and soles (Fig. 2). However, the rash of secondary syphilis can be highly variable and be localized or widespread and manifest as pustular or scaly in appearance (as opposed to theclassic maculopapular description). In intertriginous areas (particularly the anogen-ital region), these lesions can coalesce to from condylomata lata, plaques resembling flat warts or anogenital psoriasis. Gray mucus patches may also be found on the oral or genital mucosa. Because of its diverse and variable signs that resemble those of other diseases, making diagnosis challenging, syphilis is classically nicknamed “the great imitator”. All of these lesions are highly infectious through contact. Flu-like symptoms, such as sore throat, fever, and myalgias, are

common. Other end-organ manifestations, including hepatosplenomegaly, hepatitis, nephrotic syndrome, aseptic meningitis, uveitis, and generalized lymphadenopathy, have also been described. If untreated, syphilis can progress to a latent stage. There are no clinical manifestations during this stage, and the disease can only be detected via serologic testing. Screening with a non treponemal test followed by treponemal testing can confirm the diagnosis. The non-treponemal tests detect the presence of an immune system product that is produced in response to an infection with T. pallidum (a non-specific cardiolipin-cholesterol-lecithin reagin antigen). The treponemal tests detect antibodies to T. pallidum. The serologic diagnosis of syphilis relies on the combination of a reactive non-treponemal test and treponemal test. In the usual sequence of syphilis serologic testing, a non-treponemal test (RPR or VDRL) is performed followed by a treponemal test (6).

Fig. 1. *Chancre.*

Fig. 2. *Plantar rash in a patient with secondary syphilis.*

The latent stage is then subdivided into early, late, and unknown latency. Early latent syphilis occurs within a year of infection – if the date of infection is over a year ago or unknown, the patient is treated as having late latent syphilis. About one quarter of those in early latency will have a recurrence of secondary syphilis symptoms, usually within the first year. Primary and secondary syphilis carry the highest risk for vertical transmission, but even with late latent syphilis and low titers, the risk of transmission is still significant.

After a variable period of latency, the disease may progress in about one-third of those infected to late manifestations of syphilis such as cardiovascular syphilis, gummas, or tabes dorsalis. Neurosyphilis can occur at any time during the course of the infection.

According to CDC guidelines, Syphilis is treated with parenteral penicillin G (5). In very typical cases, treatment should be initiated based on clinical suspicion alone before laboratory results are available.

For primary, secondary, or early latent syphilis, a single dose of 2.4 million units IM is given. Late latent syphilis or syphilis of unknown duration is treated with 2.4 million units of benzathine penicillin G IM once a week for 3 weeks.

Despite the fact that penicillin has been used to treat syphilis for more than 60 years, there has never been a documented case of penicillin resistance.

Post treatment monitoring is essential to confirm successful eradication of syphilis.

Although not often found in a pediatric population, with the increasing incidence of syphilis infections, pediatric providers should have a low threshold for syphilis screening in adolescents and a high index of suspicion for congenital syphilis in infants.

Obtain a thorough sexual and social history, including the number of sexual partners, condom use, history of STDs in the patient and their partners, intravenous (IV) drug use, and exposure to blood products is mandatory.

Medical professionals must act as “role models” for open, positive, and inclusive parent-adolescent sex and STDs communication, should be aware of the type of misinformation available online and be prepared to combat fake news with evidence-based practice.

Pediatricians and dermatologists should assume that children with acquired syphilis have been infected through sexual abuse, unless another mechanism of transmission is identified.

Self-testing could be a safe, acceptable and effective way to increase access to syphilis testing in adolescents.

References

1. Montalti M, Salussolia A, Masini A, Manieri E, Rallo F, Marini S, Agosta M, Paternò M, Stillo M, Resi D, Guaraldi F, Gori D, Dallolio L. Sexual and Reproductive Health and Education of Adolescents during COVID-19 Pandemic, Results from “Come Te La Passi?”-Survey in Bologna, Italy. Int J Environ Res Public Health. 2022; 19(9):5147.
2. Sieving RE, Gewirtz O’Brien JR, Saftner MA, Argo TA. Sexually Transmitted Diseases Among US Adolescents and Young Adults: Patterns, Clinical Considerations, and Prevention. Nurs Clin North Am. 2019; 54(2):207-225.
3. De Seta F, Piccoli M, De Santo D, Sartore A, Grimaldi E, Panerari F, Ricci G, Guaschino S.Le malattie sessualmente trasmesse in età adolescenziale [Sexually transmitted diseases in adolescence]. Minerva Ginecol. 2000;52:(12 Suppl 1):19-24.
4. Drago F, Ciccarese G, Zangrillo F, Gasparini G, Cogorno L, Riva S, Javor S, Cozzani E, Broccolo F, Esposito S, Parodi A. A Survey of Current Knowledge on Sexually Transmitted Diseases and Sexual Behaviour in Italian Adolescents. Int J Environ Res Public Health. 2016; 13(4):422.
5. https://www.cdc.gov/sti-statistics/annual/summary.html.
6. Ortiz DA, Shukla MR, Loeffelholz MJ. The Traditional or Reverse Algorithm for Diagnosis of Syphilis: Pros and Cons. Clin Infect Dis. 2020; 71(Suppl 1):S43-S51.
7. Labudde EJ, Lee J. A Review of Syphilis Infection in Pediatric Patients. Pediatr Rev. 2024; 45(7):373-380. doi: 10.1542/pir.2023-006309. PMID: 38945983.
8. Zhang Y, Tapa J, Johnson CC, Phillips TR, Fairley CK, Ameyan W, Mello MB, Chow EPF, Chidarikire T, Ong JJ. HIV, hepatitis, and syphilis self-testing among adolescents and young adults: A systematic review and meta-analysis. J Infect Public Health. 2025; 18(6):102764.

INTERNATIONAL JOURNAL
of PEDIATRIC DERMATOLOGY

Special Issue, 2025
ISSN 3035-1006 online

Narrative Review

How to Manage Suspected Child Abuse

Fabio Arcangeli[1]

[1]*Dermatologist, G. Marconi University, Rome, Italy*

KEYWORDS

Child abuse,
Physical abuse,
Sexual abuse,
Maltreatment,
Munchausen Syndrome by Proxy

ABSTRACT

The skin is the organ most frequently exhibiting signs that may raise suspicion of abuse. For this reason, dermatologists and pediatricians are often called upon to assess whether certain cutaneous lesions are indicative of a dermatological condition or suggest the possibility of abuse. Resolving this diagnostic uncertainty is not always straightforward. Therefore, it is essential that both dermatologists and pediatricians possess thorough knowledge of dermatological disorders that may mimic signs of abuse. The author will describe some of the most frequent and clinically significant conditions.

CORRESPONDING AUTHOR

Prof. Fabio Arcangeli,
Guglielmo Marconi
Univeristy,
Rome, Italy
e-mail:
fabio.arcangeli4@gmail.com

Copyright 2025 © by World Health Academy Publishing House
This publication and/or article is for individual use only and may not be further reproduced without written permission from the copyright holder.
Unauthorized reproduction may result in financial and other penalties
DISCLOSURE: ALL AUTHORS REPORT NO CONFLICTS OF INTEREST RELEVANT TO THIS ARTICLE.

Introduction

Child abuse and neglect, as defined by the World Health Organization (WHO), include physical, emotional, and sexual abuse, as well as neglect and exploitation. These forms of maltreatment endanger the child's health, development, and dignity.

Unfortunately, most statistics show that in approximately 80% of cases, the perpetrators are the parents themselves. Abuse may take various forms: neglect, physical and sexual maltreatment, emotional abuse, and Munchausen Syndrome by Proxy.

Physical and sexual abuse often result in the appearance of skin lesions. The skin is, in fact, the organ that most readily shows signs that may raise suspicion of abuse, followed by bone fractures and injuries to soft tissues and internal organs. For this reason, dermatologists and pediatricians may be called upon to assess whether certain skin lesions are indicative of a dermatological condition or suggest the possibility of abuse. In some clinical scenarios, resolving this uncertainty may not be straightforward, which is why dermatologists and pediatricians must have thorough knowledge of all dermatological diseases that can mimic signs of abuse (1).

Ecchymotic lesions

Since these skin manifestations often result from accidental trauma, the suspicion of abuse arises not only from the type of lesion but especially from its location. When ecchymotic lesions (hematomas or bruises) appear in areas of the body that are less exposed to accidental trauma - such as the neck, nape, ears, genital regions, buttocks, and flexural areas of the limbs - physical abuse must be considered (2). However, it is not uncommon for children to sustain traumatic ecchymotic or ulcerative lesions in the genital and perigenital regions. In such cases, a thorough history is invaluable when it provides a credible reconstruction of the events. Regarding lesion location, it should be noted that non-traumatic ecchymotic lesions may also be found bilaterally in the orbital regions in cases of juvenile dermatomyositis, and unilaterally in cases of ophthalmic herpes zoster (Fig. 1).

Fig. 1. *Ophthalmic herpes zoster.*

Figurative Lesions

The configuration of skin lesions often suggests their possible origin. This is evident, for example, in cases of ecchymotic lesions that reproduce the shape of a hand (slaps), a bite, or a belt used for whipping (3). Linear-patterned lesions may also be observed in various dermatological conditions, such as certain phytophotodermatitis (Fig. 2), urticarial dermographism, or contact with jellyfish. Patterned lesions resulting from ethnic rituals should also be considered – for instance, cupping (Fig. 3), an ancient therapeutic practice involving the application of cups to the skin to create suction. This is believed to stimulate blood circulation, promote muscle relaxation, and help reduce pain and inflammation. Other similar ritual practices capable of producing patterned skin lesions include Cambodian Cao Gao and Moxibustion, a technique widespread in

Southeast Asia.

Fig. 2. *Phytophotodermatitis of the leg due to contact with asteraceae.*

Fig. 3. *Cupping.*

Excoriated Lesions

Excoriated skin lesions are rarely a reason to suspect physical violence, as they are commonly found in numerous dermatological conditions - particularly those associated with itching, such as eczema or scabies. However, when these lesions are patterned or appear in unusual distributions, they may suggest a diagnosis of dermatological factitious disorder (Fig. 4). In such cases, a gentle yet thorough medical history is essential, as these lesions are not always self-inflicted. Occasionally, they may be caused by a family member, pointing to a case of Munchausen Syndrome by Proxy, which constitutes a form of abuse.

Fig. 4. *Self-inflicted injuries.*

Burns

Wounds and burns with a rounded shape and approximately 1 cm in diameter - especially when located on exposed areas - inevitably raise suspicion of intentional injury, such as cigarette extinguishing. Clearly identifiable scalds on the face, chest, abdomen, and upper limbs are often the result of accidental contact with overheated liquids, typically spilled during meal preparation. However, immersion scalds, symmetrically located on the buttocks, lower limbs, or hands and feet in young children, warrant particular attention, as they may indicate abuse. It is also important to consider pathological conditions that can mimic superficial dermal burns, such as Staphylococcal Scalded Skin Syndrome (SSSS) - caused by bacterial toxins - and Toxic Epidermal Necrolysis (TEN) - triggered by medications (Fig. 5). In these cases, accompanying symptoms and mucosal involvement are key to establishing a differential diagnosis.

Fig. 5. *Staphylococcal Scalded Skin Syndrome (SSSS).*

Genital Region Lesions

These situations are generally difficult to interpret. This applies to traumatic lesions, which are more often accidental but may also result from mistreatment or even sexual abuse. It also applies to dermatological conditions potentially transmissible through sexual contact, such as genital warts and herpes simplex. Determining the cause of anogenital warts in children can be difficult, as the human papillomavirus (HPV) can infect children through various routes. In the case of anogenital warts occurring before the age of four, vertical transmission (prenatal or perinatal) or horizontal transmission (self-inoculation or inoculation by adults with hand warts) is more likely (4, 5). It is much less common for genital herpes to be transmitted through non-sexual means.

In young girls, innocent vulvovaginitis is not uncommon. In such cases, the integrity of the hymen - while not absolutely excluding the possibility of sexual abuse - certainly serves as an indicator in favor of innocence. Vulvar (and perianal) lesions most often mistakenly interpreted as signs of abuse are those attributable to lichen sclerosus et atrophicus (6), a skin condition that is readily identifiable by its atrophic, sclerotic appearance, whitish lard-like patches, the presence of an inflammatory halo during active phases (Fig. 6), and - most notably - persistent itching.

Other conditions that may mimic signs of abuse include streptococcal perianitis, pyramidal perianal protrusion, idiopathic scrotal edema, and perianal epidermal nevus.

Fig. 6. *Vulvar and perianal lichen sclerosus et atrophicus.*

Conclusions

It is not always easy to correctly assess cases involving ecchymotic lesions, wounds or abrasions, unusual burns, potentially sexually transmitted lesions, and especially any type of injury located in the genital and perigenital regions. Great care must be taken to distinguish pathological conditions from direct signs of abuse. However, in any situation where suspicion is justified, it is a duty to report the matter to the Judicial Authority, which will then initiate appropriate investigations and make decisions accordingly.

References

1. Focardi M, Gori V, Romanelli M, et al. "Mimics" of Injuries from Child Abuse: Case Series and Review of the Literature. Children. 2024; 11(9):1103.
2. Laskey A, Sirotnak A. Child Abuse: Medical Diagnosis and Management. American Academy of Pediatrics. 4th Edition 2024.
3. Brown CL, Yilanli M, Rabbitt AL. Child Physical Abuse and Neglect. [Updated 2023 May 29]. In: StatPearls [Internet]. Treasure Island (FL). StatPearls Publishing. 2025.
4. Awasthi S, Ornelas J, Armstrong A, Johnson JA, Eisen DB. Anogenital warts and relationship to child sexual abuse: Systematic review and meta-analysis. Pediatric dermatology. 2021; 38(4):842-850.
5. Alfieri A, Pudjiati SR, Yefta, Danarti R. Anogenital warts in children: The dilemma of distinguishing between sexual abuse or other transmission routes. European Journal of Pediatric Dermatology. 2024; 34(2):81-84.
6. Abder-Rahman H, Habash I, Hussein A, Al-Shaeb A, Elqasass A, Qaqish LN. Genital lichen sclerosus misdiagnosis: Forensic insights. Forensic science, medicine, and pathology. 2024; 20(4):1444-1447.

INTERNATIONAL JOURNAL
of PEDIATRIC DERMATOLOGY

Special Issue, 2025
ISSN 3035-1006 online

Narrative Review

How to Manage Juvenile Acne

Marialisa Feliciangeli[1]

[1]*Dermatologist, Rimini, Italy*

KEYWORDS

Acne vulgaris
Juvenile Acne
Adolescent

ABSTRACT

This paper offers a structured synthesis of the management of Juvenile Acne, placing particular emphasis on communication with the patient and their parents. The content is organized into six principal components: three pertaining to diagnostic evaluation and three addressing therapeutic intervention.

CORRESPONDING AUTHOR

Marialisa Feliciangeli,
Dermatologist,
Rimini, Italy

e-mail: marialisa@arcangelifeliciangeli.it

Copyright 2025 © by World Health Academy Publishing House
This publication and/or article is for individual use only and may not be further reproduced without written permission from the copyright holder.
Unauthorized reproduction may result in financial and other penalties
DISCLOSURE: ALL AUTHORS REPORT NO CONFLICTS OF INTEREST RELEVANT TO THIS ARTICLE.

Introduction

Managing Juvenile Acne (JA) is, of course, a complex topic, as evidenced by the hundreds of studies published over the past decades, numerous attempts to classify the severity of the condition, and the various guidelines concerning treatment. The choice of therapy should be principally based on the type of lesion and the severity of the acne, but psychosocial disability relating to the disease and the presence of scarring may also influence the approach to treatment. What is proposed here is a summary, with particular emphasis on communication with the patient and their parents, divided into six key points: three related to diagnostic assessment and three focused on treatment.

Diagnostic Assessment

1. Never underestimate the issue, but always investigate the adolescent's psychological aspects and the role of the parent.

It has been well established that the impact of Juvenile Acne on emotional and social quality of life is greater than that of other chronic conditions such as psoriasis, asthma, and epilepsy (1). JA is often the first persistent psychological distress linked to self-image and plays a critical role in the adolescent's identity formation (2).
Notably, the impact on quality of life is not strictly correlated with the objective severity of the acne. Because of this disconnect between clinical severity and psychological burden, it is essential to carefully assess the adolescent's actual experience of the condition and their relationship with their parents (3).

The adolescent with acne is almost always accompanied to the consultation by a parent, raising the question of whether to address the adolescent or the parent. It is appropriate to engage with both, avoiding the exclusion of either.

This dual-channel communication - what becomes a "triangulation" between doctor, adolescent, and parent - generally favors pediatricians, who are already familiar with the parent-child dynamic. However, it still requires a solid understanding of adolescent psychology, especially in terms of body-centered identity exploration, issues related to peer group integration, and the evolving nature of their relationship with their parents.
Two of the most frequent situations encountered are:
a) The parent who tends to speak and act on behalf of the adolescent, taking control over the perception and evaluation of the condition as well as the request for treatment. This often corresponds with an adolescent who appears indifferent, defensive, or even hostile, and who tends to deny their emotional distress. In these cases, it is important to discourage the parent's tendency to "take over" and instead establish the adolescent's active involvement as a necessary condition, both in communication and in following the treatment plan.
b) The parent who is unaware or minimally aware of their child's psychological distress. In these situations, the parent should be asked to observe their child's emotional and behavioral dynamics more carefully, with the aim of supporting them more effectively throughout the therapeutic journey.

2. Carefully assess the primary lesions present on both the face and torso, comedones, microcysts, papules, pustules, nodules, and cysts.

This allows for the clinical classification of JA into non-inflammatory, superficial inflammatory, and deep inflammatory types. Based on the number and predominance of these lesions, the condition can also be categorized by severity: Mild, Moderate, or Severe (4).

It is also important to identify excoriated lesions, which are very common and often appear crusted (Fig. 1). These are clear indicators of psychological distress in the adolescent and play a critical role in the risk of scar development.

Any therapeutic choice should be tailored not only to the adolescent's psychological burden but also to the scarring risk associated with their lesions.

Fig. 1. *Excoriated lesions in acne patients.*

3. Always rule out endocrine disorders in female patients.

The association of Juvenile Acne with Androgenetic Alopecia and/or Hirsutism (Fig. 2) is particularly significant, as both conditions are mediated by androgens and are therefore expressions of hyperandrogenism (HA).

HA is most commonly primary, due to increased peripheral action of androgens resulting from heightened receptor sensitivity, and less frequently secondary. Secondary HA may stem from excessive adrenal androgen production (5% of cases), typically related to late-onset Congenital Adrenal Hyperplasia, or from ovarian origins (95%), most commonly Polycystic Ovary Syndrome (PCOS) or PCOS-like syndromes, the latter being very common in adolescent girls with acne.

Although primary HA is far more prevalent, it is crucial to identify secondary forms to ensure appropriate therapeutic intervention.

Therefore, in all girls presenting with acne, both objective evaluation (starting with hair and body hair) and a thorough patient history are essential. A key factor is assessing the regularity of menstrual cycles. If a patient experiences fewer than 9 menstrual periods per year, this alone allows for a presumptive diagnosis of secondary HA. That diagnosis must then be confirmed and further investigated through ovarian ultrasound and/or laboratory testing, to be performed within the first 5 days of the menstrual cycle. These tests should include adrenal-derived androgens, ovarian hormones, pituitary regulators of ovarian function (with a critical focus on the FSH/LH ratio) insulinemia, considering the frequent link between PCOS and hyperinsulinism.

Fig. 2. *Acne (a) associated with hirsutism (b) and androgenetic alopecia (c).*

Therapy

1. Promoting Therapeutic Adherence

Large-scale studies conducted over many years have demonstrated that inadequate Therapeutic Adherence (TA) is responsible for treatment failures in 40-60% of adolescents. Their parents, too, often lack understanding of the underlying causes of unsuccessful acne management, which is largely due to persistent misconceptions. To promote effective TA, it is essential to dedicate time to explain these causes clearly-debunking widespread myths such as: the supposed central role of diet (even in adolescents who are of normal weight and without endocrine disorders), Iiproper cleansing routines, use of makeup, sun exposure. Instead, attention should be given to explaining the true contributing factors, including: genetic predisposition, the crucial relationship between hormones and skin physiology. This also provides justification for in-depth patient history and, when necessary, instrumental and/or laboratory investigations, especially in female patients.

To support Therapeutic Adherence, it is also recommended to schedule follow-up appointments every 2 - 3 months, or as needed in cases of side effects caused by topical and/or systemic treatments.

2. Proposing treatment through shared decision-making.

To achieve this goal, it is first essential to provide explanations regarding the severity scale of Juvenile Acne, alongside a simplified overview of potential therapeutic steps, so that the most appropriate course of action can be evaluated together. Beyond the many clinical guidelines developed over the years (5, 6) - culminating in the most recent recommendations from the American Academy of Dermatology - and the various clinical practice criteria that each dermatologist or pediatrician may choose to follow in treating JA and any associated endocrine disorders, it remains crucial to dedicate time to communicating with the patient and their parent, in order to fully involve them in the therapeutic decision-making process.

3. Do Not Fear the Side Effects of Topical Medications.

Considering that in approximately one-third of cases, topical treatment for Juvenile Acne - whether using retinoids, benzoyl peroxide, or their combinations - can cause varying degrees of irritant contact dermatitis (Fig. 3), it is important to emphasize that symptoms such as erythema, dryness, peeling, and burning may appear even after weeks or months of use. These effects are often linked to excessive quantity or frequency of application, depending on the adolescent's skin phototype. It is therefore essential to inform both the adolescent and their parent about the potential side effects of topical therapies. Explain clearly not only the timeline but also the practical usage methods with a demonstration using any moisturizer available in the clinic. In addition, guidance should be provided on what actions to take if these side effects occur: suspend application of the product, increase the use of a moisturizer (typically recommended alongside the medication). Once the dermatitis resolves, reintroduce the anti-acne topical agent with reduced quantity and/or frequency. Only in more significant cases, and under a physician's recommendation, should a topical corticosteroid be applied for a few days.

Fig. 3. *Irritant contact dermatitis after application of tretinoina cream.*

References

1. Mallon E, Newton JN, Klassen A, Stewart-Brown SL, Ryan TJ, Finlay AY. The quality of life in acne: a comparison with general medical conditions using generic questionnaires. Br J Dermatol. 1999;140(4):672-6. doi: 10.1046/j.1365-2133.1999.02768.
2. Fabbrocini G, Cacciapuoti S, Monfrecola G. A Qualitative Investigation of the Impact of Acne on Health-Related Quality of Life (HRQL): Development of a Conceptual Model. Dermatol Ther (Heidelb). 2018;8(1):85-99. doi: 10.1007/s13555-018-0224-7.x
3. Purvis D, Robinson E, Merry S, Watson P. Acne, anxiety, depression and suicide in teenagers: a cross-sectional survey of New Zealand secondary school students. J Paediatr Child Health. 2006;42(12):793-6. doi: 10.1111/j.1440-1754.2006.00979.x.
4. Patel DP, Bernardis E, Yan AC. The patient-centered acne severity scale study. Pediatr Dermatol. 2017;34(6):656-660. doi: 10.1111/pde.13262.
5. Nast A, Dréno B, Bettoli V et al. European evidence-based (S3) guideline for the treatment of acne - update 2016 - short version. J Eur Acad Dermatol Venereol. 2016;30(8):1261-8. doi: 10.1111/jdv.13776.
6. Reynolds RV, Yeung H, Cheng CE et al. Guidelines of care for the management of acne vulgaris. J Am Acad Dermatol. 2024;90(5):1006.e1-1006.e30. doi: 10.1016/j.jaad.2023.12.017.

INTERNATIONAL JOURNAL
of PEDIATRIC DERMATOLOGY

Special Issue, 2025
ISSN 3035-1006 online

Narrative Review

Vitiligo in Childhood: Being There for the Young Patients and Their Families

Evridiki Tsoureli-Nikita[1]

[1]*2nd Dermatology Department, Attikon Universty Hospital, EKPA Medical school, Athens, Greece*

KEYWORDS

Vitiligo,
Segmental vitiligo,
Non-segmental vitiligo,
Psycho-relational impact

ABSTRACT

Following the presentation of the epidemiological and clinical features of the disease, the author emphasizes its psycho-relational impact, particularly during childhood, and underscores the importance of an appropriate approach by both caregivers and the peer community.

CORRESPONDING AUTHOR

Evridiki Tsoureli-Nikita,
2nd Dermatology Department, Attikon Universty Hospital, EKPA Medical school, Athens, Greece

e-mail: evinikita@gmail.com

Copyright 2025 © by World Health Academy Publishing House
This publication and/or article is for individual use only and may not be further reproduced without written permission from the copyright holder.
Unauthorized reproduction may result in financial and other penalties
DISCLOSURE: ALL AUTHORS REPORT NO CONFLICTS OF INTEREST RELEVANT TO THIS ARTICLE.

Vitiligo is an acquired pigmentary disorder (1), characterized by sharply demarcated, variably shaped depigmented macules surrounded by normal skin, which can also affect muco-cutaneous areas. The most common areas affected are T the face, dorsa of the hands, nipples, axillae, umbilicus, sacral, inguinal and anogenital regions with an important psychological impact for the patient. It constitutes the most common depigmenting disorder, with an estimated prevalence of 0.5-2% of the population worldwide in children and adults and in both sexes and races. Fifty percent of the patients will develop clinical signs before the age of 20 and a 25% before the 9 years of age. (Fig.1). Clinically, it is classified into two major forms, non segmental vitiligo (NSV) localized or generalized (Fig. 2), and segmental vitiligo (SV) (Fig. 3). Intrinsic abnormalities suggest a gradual reduction in the number of the melanocytes, as well as loss of function (Fig. 4). The association with autoimmune disorders and organ-specific antibodies as well as the fact that repigmenting therapies have immune-modulating effects, indirectly support the idea of an autoimmune pathogenesis (2). Non the less, Patients with vitiligo and their "first degree" relatives have a higher incidence of other autoimmune conditions (including thyroiditis, pernicious anemia, Addison's disease, systemic lupus erythematosus and inflammatory bowel disease) than the general population. Its management is challenging, and current therapeutic concepts on vitiligo focus on the cytokine and signaling pathways, including JAK kinase, which seem to offer the most promising results.

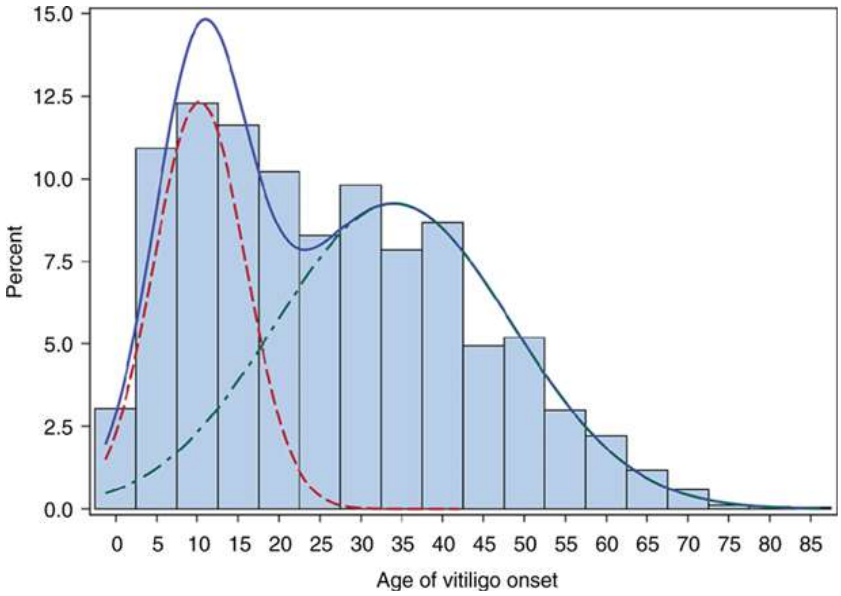

Fig. 1. *Age at which vitiligo appears.*

Fig. 2. *Generalized non segmental vitiligo.*

Fig. 3. *Segmental vitiligo, under Wood's lamp.*

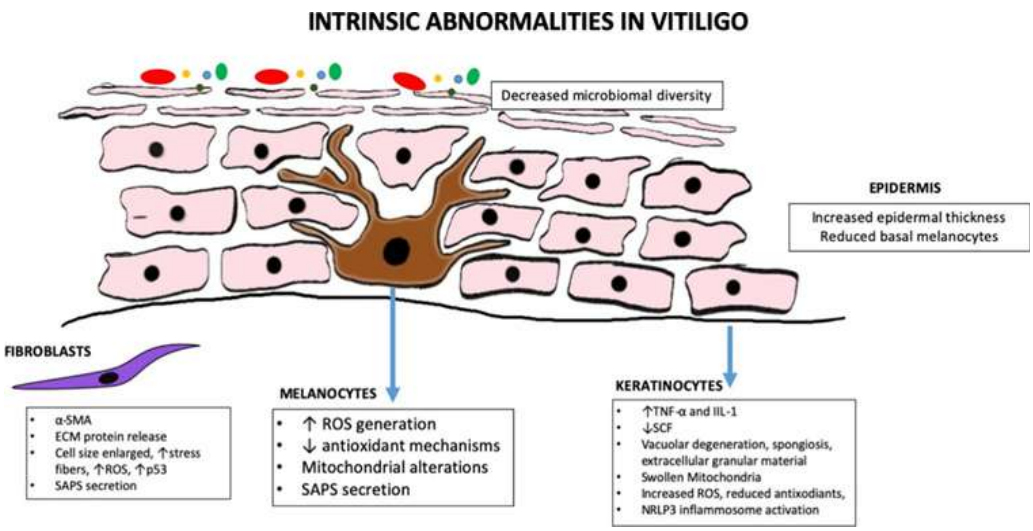

Fig. 4. *Abnormalities in vitiligo.*

Vitiligo is a disfiguring disorder with an important effect on the self-esteem and social life of patients. Therefore, its management is challenging and a trusting relationship between the doctor and the patient is crucial. Worldwide organizations, such as the British vitiligo society, are engaging in major kids-friendly campaigns, in order to manage this, at times, disfiguring disease with empathy and a bit of wit, non only with regards to children, but also towards their parents and carers.

Children are small human beings, not young adults. It is mandatory to explain and take them through every step of the way as far as it concerns the "how", "what is it", but most importantly the "why me"? The psychological fragility of the children and adolescents, makes them susceptible to all kinds of assumptions, especially in our age where misinformation through the social media and various influencers, reign hazardously. Demonstrating the clinical aspect with photos through campaigns, is key to recognizing the disease and seek specialist help. Children and parents/carers, must be informed thoroughly with simple vocabulary – children even more importantly- about the very nature of vitiligo, the pathogenesis, the possible development and the treatment options. Sincerity is a major feature, underlining the exclusively aesthetic discomfort of the disease. It is of highly importance to inform the whole

family that despite the numerous available treatments, there is always an individual response that can oscillate from non response, to an improvement that could, though, relapse in time.

Parents-carers need also to be educated on how to deal with a child affected by vitiligo by accepting, understanding and embracing theirs children's needs for the truth, without burring heads in the sand due to fear and disappointment. The more a child sees a sincere and honestly interested parent, the less tormented will it be by the feelings of inadequacy and lack of confidence. Lets not forget that children, especially in school environments can be ruthless and treat their "different" companions with cruelty through bullying, creating hostility and social exclusion.

Last but not least, doctors and parents/carers should also embrace young children with vitiligo by demonstrating that they are not alone in nature. Vitiligo is a condition affecting many other species in the animal world, providing them with astonishing beauty. Additionally, numerous influencers and public figures have come out in the last few years, demonstrating that being different means being unique.

Vitiligo is a condition of an aesthetic importance which doesn't affect other organs, and can be controlled through various systemic and topical treatments, as well as cosmetic camouflage. When it comes to affected children, a confident adult, doctor/parent-carer which stands by their side with calmness and acceptance of the condition, is all it takes, in order to have a happy and confident child, able to deal with this chronic condition as time goes by.

References

1. Gianfaldoni S, Tchernev G, Wollina U, Lotti J, Satolli F, França K, Rovesti M, Lotti T. Vitiligo in Children: A Better Understanding of the Disease. Open Access Maced J Med Sci. 2018; 20:6(1):181.

2. Senescahl J, Boniface K, D'Arino A, Picardo M. Pigment Cell Mel Res. 2021; 34(2):236-243.

INTERNATIONAL JOURNAL
of PEDIATRIC DERMATOLOGY

Special Issue, 2025
ISSN 3035-1006 online

Narrative Review

Pityriasis Rosea

Matteo Ferrara[1]

[1]*Family pediatrician, Olevano sul Tusciano, Salerno, Italy*

KEYWORDS

Pityriasis Rosea
Erythematous-desquamative rash
Herald patch
Epidermolytic collarette

ABSTRACT

The author provides an updated overview of Pityriasis Rosea, addressing its epidemiological, etiological, clinical - particularly emphasizing the increasingly frequent atypical variants - diagnostic, dermoscopic, and therapeutic aspects

CORRESPONDING AUTHOR

Matteo Ferrara,
Family pediatrician,
Olevano sul Tusciano,
Salerno, Italy

e-mail: drmatteoferrara@gmail.com

Copyright 2025 © by World Health Academy Publishing House
This publication and/or article is for individual use only and may not be further reproduced without written permission from the copyright holder.
Unauthorized reproduction may result in financial and other penalties
DISCLOSURE: ALL AUTHORS REPORT NO CONFLICTS OF INTEREST RELEVANT TO THIS ARTICLE.

Introduction

Pityriasis Rosea of Gibert or Gilbert? Definying it Pityriasis Rosea of Gilbert it is still tempting…but with a mistake (1, 2). Has been described in a complete way by Camille Melchior Gibert, dermatologist (Paris 1797 – 1866) in his book: "*Maladies de la Peau*" in 1860 (3). The erythematous-desquamative lesions are distinctive in terms of their shape and typical progression, allowing a fast glance diagnosis or even on the phone.

Aetiology

Although it supports the infectious aetiology, the contagiousness has never been proven, even though small epidemics or the involvement of several members of the same family have been described in the literature (4). In support of the infectious aetiology, the onset was preceded by prodromal symptoms such as malaise, nausea, fever, headache, joint and gastrointestinal pain. The reactivation of latent human herpes infections (HHV6/7) (5) is assumed to be the most likely aetiology.

Epidemiology

The approximate incidence of Pityriasis Rosea (PR) ranges between 0.5 and 2%. Adolescents and adults between the ages of 15 and 30 are most frequently affected, but young children can be affected too. The littlest patient, of only three months of age, has been described in literature (6).

Mortality/morbility

PR is a benign self-limited disease associated with mild morbility with rash and occasional pruritus (7). It has can been associated with neonatal hypotonia, hyporeactivity, and premature delivery. An increased risk of miscarriage may occur, especially mothers who developed pityriasis rosea whitin the first 15 weeks of their pregnancy (8, 9).

Physiopathology

The physiopathology of PR is not entirely understood. However, a lack of natural killer (NK) cell and B cell activity PR lesions have been noticed, suggesting a predominantly T-cell mediated immunity. Increased CD4+ T - cells and Langerhans cells are present in the dermis, possibility reflecting viral antigen processing and presentation. In the blood, an increase in interferon alpha and gamma is observed (9, 20).

Histopathology

Hyperkeratosis, focal spongiosis, reduction/absence of the granular layer, perivascular and interstitial lymphocytic dermal infiltrate with epidermotropism are the most significant findings that can be observed (9).

Clinical

In its typical or complete forms, it appears in two phases:

Phase 1. Appearance of "*mother patch*" or "*herald patch*" or "*initial medallions*" located on the trunk (50% of cases), buttocks, proximal limbs or neck. It is generally single, round or oval in shape, with a larger diameter following the cutaneous tension lines of Langer (Fig. 1), erythematous-squamous with a cigarette-paper appearance, 2-10 cm in diameter, and yellowish-pink in colour. In this phase the dermatoscope is very important (10, 11).

Fig. 1 *Typical herlad patch.*

Phase 2. After 1 to 2 weeks, a skin eruption appears with patches smaller than the initial *herald patch*, which persists (Fig. 2). These are generally non-confluent and rapidly spread across the trunk and the proximal limbs in a centripetal distribution. They are also arranged along Langer's lines, forming a whorled pattern on the chest, circular under the armpits, horizontal on the abdomen, and a Christmas tree-like pattern on the back (12).

Fig. 2 *The eruption of numerous small.*

Small patches

In children the itching sensation is weak or absent in comparison with the adult patients (7). The rashes usually last for 5 weeks and resolve by 8 weeks in more than 80% of patients. The relapsing occurs in 1,8-3,5% of the cases (5). Dermatoscopy with epiluminescence highlights an epidermolytic collarette at the level of the small patches (10), which typically show a yellowish background color and a disorganized (patchy) distribution of red dots (capillary vessels) (11).

Over time, the new lesions become progressively smaller, less numerous, and less persistent. The *herald patch* regresses first (13). Generally, the oral mucosa is not affected, although the literature reports pinpoint hemorrhages, erosions and ulcerations, erythematous macules, and geographic tongue in this area (14). The skin lesions most often resolve with hypochromic outcomes, and rarely with hyperchromic ones.

Differential diagnosis

The main dermatological pathologies that enter into differential diagnosis with RP are erythema multiforme, guttate psoriasis, lichen planus, parapsoriasis, pediatric syphilis, pityriasis alba, tinea corporis, tinea versicolor, nummular eczema.

PR-like rashes have been reported after vaccinations against influenza A (H1N1), diphtheria, smallpox, pneumococcus, covid-19 and after taking isotretinin, nimesulide, rebinafine, dupilumab, rituximab, imatinib, adalimumab (20).

PR-like eruptions differ from classic pityriasis rosea by the absence of the herald patch and by a more inflammatory appearance of the lesions, which often have a reddish-violet color and are intensely pruritic.

The various atypical (15-20)

Not all patients with PR present with the typical form. Atypical variants are observed in approximately 20% of cases. Atypia may refer to differences in lesion morphology, size, number, distribution, symptoms, or clinical course.

Morphology: papular, vesicular, purpuric-haemorrhagic, psoriasic, urticaria-like, lichenoid, multiforme-like, follicular.

Morphology and Topography: circinata and marginata of Vidal.

Herald patch: absent, 2 or more, delayed, persistent.

Number: few or many giant lesions

Topography: face, neck, armpit, limb(s), groin, lateral back, unilateral (dermatomal)

Course: abortive, rapid onset (less than two weeks), relapsing, faster course.

Persistent: longer than 3 months with asthenia, insomnia and other systemic symptoms.

Treatment/Management

PR is a self-limiting condition, so despite its striking appearance, no treatment is strictly necessary, and none has proven to be significantly effective. In addition to general measures such as the use of emollients and gentle cleansing with bath oils, some patients benefit from cautious sun exposure, the use of macrolides, and sedating antihistamines in cases of itching (20).

References

1. Parsons JM. Pitiriasis rosea update. J.Am.Acad. Derm. 1986;15:159-165.
2. Hartley H et al. Pityriasis rosea. Ped in Rew. 1999;8:266-70.
3. Gibert CM. Traite' pratique des maladies de la peau et de la syhilis.3rd.Paris:Plon. 1860; p 402.
4. Miller TH. Report of three causes in one family with clinical variations in two of them. Arch Derm Syfilol. 1941;194:44:66-68.
5. Drago F, Ciccarese G, Broccolo F et al. Pityriasis rosea in children: clinical features and laboratory investigations. Dermatology. 2015;23(1):9-14.
6. Hyatt W. Pityriasis rosea in a three months old infant. Arch Pediatr. 1960;77:364-368.
7. Berti I. La pitiriasi rosea. Medico e Bambino. 2009;9:588-9.
8. Drago F. Pityriasis rosea: An update with a critical appraisal of its possible herpes viral etiology. J Am Acad Dermatol.2008;61:303-318.
9. Drago F, Broccolo F, Zaccaria E et al. Pregnancy outcome in patients with pityriasis rosea. J Am Acad Dermatol. 2008;58:578-83.
10. Vasisht S, Kansal NK. Dermoscopic features of pityriasis rosea. BMJ Case Rep. 2023;16(10): e256304.
11. Chuh AT. Collarette scaling in pityriasis rosea demonstrated by digital epiluminescence dermatoscopy. Aus. J. Dermatol. 2001;42:288-290.
12. Chuh AT. Rash orientation in pityriasis rosea: a qualitative study. Eur J Derm. 2002;(12):253-6.
13. Bonifazi E. Dermatiti eritemato-desquamative. Rosea, Eczematitdi, Pitiriasi lichenoide. Eur J Pediatr Dermatol. 1994;4:113-18.
14. Vidimos AT, Camisa C. Tongue and cheek: oral lesions in pityriasis rosea. Cutis. 1992;50:276-80.
15. Klauder JK. Pityrisis rosea with particular reference to its unusual manifestations. JAMA. 1924;82:178-

83.
16. Chuh A, Zawar V, Lee A. Atypical presentations of pityriasis rosea: case presentations. J Eur Acad Dermatol Venereol. 2005;19:120-6.
17. Verbov J. Purpuric pitiryasis rosea. Dermatologica. 1980;160:142-4.
18. Imamura S, Ozaki M, Oguchi M et al. Atypical pityriasisi rosea. Dermatologica. 1985;171:474-77.
19. Zawar V. Giant pityriasis rosea. Indian J. Dermatol. 2010;55(2):192-194.
20. Leung AKC, Lam JM, Leong KF, Hon KL. Curr Pediatr Rev. 2021;17(3):201-211.

INTERNATIONAL JOURNAL
of PEDIATRIC DERMATOLOGY

Special Issue, 2025
ISSN 3035-1006 online

Narrative Review

Current Advances in Photoprotection

Annalisa Patrizi[1]

[1]*Dermatologist, Professor Alma Mater Studiorum, University of Bologna, Bologna, Italy*

KEYWORDS

Solar light
Ultraviolets
Sun exposure
Skin cancer
Photoprotection
Photoprotective clothing
Sunscreen

ABSTRACT

The author provides an up-to-date overview of the best photoprotection strategies to adopt during childhood to prevent acute and long-term health damage related to inappropriate sun exposure.

CORRESPONDING AUTHOR

Patrizi Annalisa,
Dermatologist
Professor Alma Mater Studiorum,
University of Bologna,
Bologna, Italy
tel: +39.3396700411 / 3346157448

e-mail:annalisa.patrizi@unibo.it

Copyright 2025 © by World Health Academy Publishing House
This publication and/or article is for individual use only and may not be further reproduced without written permission from the copyright holder.
Unauthorized reproduction may result in financial and other penalties
DISCLOSURE: ALL AUTHORS REPORT NO CONFLICTS OF INTEREST RELEVANT TO THIS ARTICLE.

Introduction

The spectrum of solar light encompasses ultraviolets (UV), infrared rays and visible light. Damage of the skin due to sun exposure is mainly caused by ultraviolet A (UVA) and ultraviolet B (UVB) that have been shown to increase the risk of developing multiple skin damagies including photodistributed pigmentary alterations, nevi, and skin malignancies (1, 2). Ultraviolet C rays are almost fully absorbed by the ozone layer. UV levels are higher as altitude and sun height increases, and cloudiness and latitude decrease. Other environmental factors that increase UV levels are the ozone layer and the reflective capacity of the Earth's surface: for example, snow reflects 80% of UV rays and dry sand about 15% and sea water foam 25%. The photoprotection of the healthy child must also evaluate the Fitzpatrick skin phototypes (Table I) (3).

Table I. *Fitzpatricl Scale. A numerical system used to classify a person's skin type based on its response to ultraviolet light.*

Fitzpatrick Scale					
I	**II**	**III**	**IV**	**V**	**VI**
Very Fair Always burns Cannot tan	**Fair** Usually burns Sometimes tans	**Medium** Sometimes burns Usually tans	**Olive** Rarely burns Always tans	**Brown** Rarely burns Tans easily	**Dark Brown** Never burns Always tans

Moreover, children spend a lot of time outdoors They tend to stay in the sun longer than necessary. The daily exposure to UV rays during recreational activity of kindergarten children is higher than that of outdoor workers and retirees. At 18 they have consumed 50% of the sun quota of life.

Photoprotection and educational campaigns

Photoprotection is defined as the prevention against damaging effects of intense solar radiation. Photoprotection includes avoiding the sun, staying in the shade when outdoors, wearing photoprotective clothing including a wide-brimmed hat, and sunglasses, and the use of sunscreens (2). Photoprotection is particularly important in the pediatric age as the first sun exposures are essential for life. In fact, sunburn in childhood is an important risk factor for the future development of skin cancers and should be avoided. Avoidance of the use of tanning beds is an important component of education for teenagers. Children's skin is more susceptible to sun damage for a number of reasons, including certain anatomical and functional aspects in children under 2 years of age and habits that predispose to greater sun exposure during the first 2 decades of life. Unfortunately, the mothers most careful to avoid sunburns in their children are those whose children have already suffered a sunburn. It should also be noted that children's games in kindergartens and beaches are often located in the sun and this keeps them away from the shade. In order to raise awareness among children, families and teachers, educational campaigns have been proposed in primary and secondary schools such as " no hat no play"; "il sole per amico for kids and for young".

In adolescents between 13 and 15 years of age, the understanding of solar risk is modest and only about 15% know that the time between 11 and 16 should be avoided. On the contrary, this is their preferred time slot (60% of males and 85% of females). Adolescents after an educational campaign change their knowledge, but not their behavior. In Italy, a study of 746 young people between 16 and 22 years of age has shown good information on the risks associated with sun exposure, but a conduct completely careless of such information (4). So, education campaigns are to be provided during primary school which appears to be the most propitious period for communication.

Photoprotection with clothing (5)

Photoprotection with clothing is essential. In this regard, technologically advanced fabrics have also been produced in Italy to protect the skin from the pitfalls of the sun's rays. These are fabrics that contain zinc oxide and titanium dioxide molecules between the fibers. These natural or synthetic fabrics with different colors are able to effectively protect the skin from the action of the sun's rays. Their level of protection is indicated by the abbreviation UPF (Ultraviolet Protection Factor). The colors are mostly bright or dark and the degree of protection is indicated as UPF 50+ or 30+ or 15+ Below these values the clothing is no longer protective. These garments have the UPF number on the label, a yellow sun with shading and the law number (EN 13758-2).

Topical photoprotectors

Finally, let's talk about topical photoprotectors (6, 7). They are any product (oil, cream, gel, spray) intended to be placed in contact with the skin for the exclusive and main purpose of protecting it from UV rays by absorbing or reflecting them. The World Health Organization (WHO) states that topical photoprotectors are the last line of defense of the skin from the sun on areas that cannot be otherwise protected. However, prolonged exposure to the sun with topical photoprotectors induces false safety and this contributes to increased incidence of skin cancer and melanoma.

What characteristics should topical photoprotectors have? They must be harmless, pleasant, resistant to water and sweat, photostable and broad-spectrum against UVB and UVA.

The label of these products requires the following to be indicated:

1) Water proof (resistance to 4 baths of 20 minutes at a distance of 20 minutes from each other) or water resistent (2 baths);
2) Circles with the words UVA and UVB inside;
3) Extent of protection expressed by Sun Protection Factor - SPF (UVB) and Persistent Pigment Darkening - PPD (UVA) parameters (Fig. 1).

PPD must be at least one-third SPF

PPD (Persistent Pigment Darkening)	PA (Protection Grade of UVA)
2~4	PA+
4~8	PA++
8~16	PA+++
16~	PA++++

Fig. 1. *Relationship between PPD and UVA protection level.*

SPF is a measure of how much solar energy (UV radiation) is required to produce sunburn on protected skin (i.e., in the presence of sunscreen) relative to the amount of solar energy required to produce sunburn on unprotected skin. As the SPF value increases, sunburn protection increases (Table II).

Tabel II. *SPF value and relative exposure time needed to produce sunburn.*

Unprotected Exposure	SPF 15	SPF 30	SPF 50
10 minutes = 100% UV	150 minutes (≈ –93% UV)	300 minutes (≈ –97% UV)	500 minutes (≈ –98% UV)

Application of sunscreens

How do you apply sunscreen products?
1) Apply sunscreen all over the body at least 30 minutes before exposure;
2) Apply sunscreen in the right amount (2 mg/cm2) and uniformly so that it is effective;
3) Do not use the product after the Period After Opening (PAO) which must be indicated in the product and packaging

The use of a topical photoprotector does not appear to be indicated below 6 months (FDA), for some products under one year. Photoprotection in children, especially in early childhood, should include hats, clothing, spectacles and limitation of direct exposure to sunlight. Inorganic filters not in the form of nanoparticles should be preferred. These are the indications of the World Health Academy of Dermatology and Pediatrics (WHA-D&P) which hopes that sunscreens will be considered and regulated by health institutions as drugs to increase their efficacy and safety. It is also recommended to prefer fragrance-free and water-resistant products, biodegradable and in eco-sustainable packaging.

Sunscreen and children

Sunscreen and children:
1) there are no precise rules for children;
2) physical screens and safe filters should be used mainly (e.g. Tinosorb);
3) protection indices between 30 and 50;
4) optimal ratio of UVA to UVB protection;
5) apply sunscreens correctly every 2/3 hours.

Numerous substances are added to the real photoprotector to form the final product. They have an emollient, antioxidant and immunostimulant purpose. Among them we mention, among others: Vit A, C, E; Aloe vera; Sorbitol; Dimethicone; Glycerin; Arginine; Thermal waters; Hexylresorcinol and Panthenol.

Mexoryl 400 and UVMune 400 (8)

UV rays affect our skin to a greater or lesser extent depending on the time of day, the season, the altitude and the weather. According to their wavelengths, we distinguish between UVB (rays between 280 and 320 nm), short UVA (between 320 and 340 nm), long UVA (from 340-400 nm) and in this range the ultra-long UVA (between 380 and 400 nm). FDA approved Mexoryl 400 as a filter for 380-400 NM ultra long UV rays. This product is now approved in Italy in the formula UVMune 400. With UVMune 400, the solar filtration range is increased by 20 nm and this new generation of filter powered by Mexoryl represents the first product that filter the broad UV spectrum: it is a major scientific advance for lifelong protection from ultraviolet radiation. Previous generation sun filters have insufficiently protected skin against ultra-long UVA rays. These long UVA rays penetrate the epidermis the most and are among the main causes of skin aging. They also contribute to the development of skin cancer, along with other UVA and UVB rays. No sun filter was able to block efficiently ultra-long UVA rays from 380 nm which alone accounts for 30% of UV.

Sunscreens and Vitamine D (9)

Can sunscreens with high protection cause a Vitamin D deficiency? Although the question is legitimate, the answer is negative: no Vit D deficiency is observed using topical photoprotectors with a high degree of protection.

References

1. Geisler AN, Austin E, Nguyen J, Hamzavi I, Jagdeo J, Lim HW. Visible light. Part II: Photoprotection against visible and ultraviolet light. J Am Acad Dermatol. 2021;84:1233-1244.
2. Pellacani G, Lim HW, Stockfleth E, Sibaud V, Ortiz Brugués A, Saint Aroman M Photoprotection: Current developments and controversies. Eur Acad Dermatol Venereol. 2024 Jul:38 Suppl 5:12-20.
3. Fitzpatrick TB. The validity and practicality of sun-reactive skin types I through VI. Arch Dermatol. 1988;124:869.
4. Monfrecola G, Fabbrocini G, Posteraro G, Pini D. What do young people think about the dangers of sunbathing, skin cancer and sunbeds? A questionnaire survey among Italians. Photodermatol Photoimmunol Photomed. 2000;16:15-8.
5. Malbasa C, Baron ED. Photoprotection with clothing and sunscreens. G Ital Dermatol Venereol. 2010;145:509-14.
6. Petersen B, Wulf HC. Application of sunscreen--theory and reality. Photodermatol Photoimmunol Photomed. 2014;30:96-101.
7. Bennett LS., Khachemoune A. Dispelling myths about sunscreen. J Dermatolog Treat. 2022;33:666-670.
8. Piccolo V, Salari P. Filtri solari: i progressi della tecnologia ampliano lo spettro della protezione. Update per il Pediatra [Internet]. Pisa (Italy): Pacini Medicina; [cited 2025 Nov 3]. Available from: https://www.pacinimedicina.it/update_pediatra/
9. Passeron T, Bouillon R, Callender V, Cestari T et al. Sunscreen photoprotection and vitamin D status. Br J Dermatol. 2019;181:916-931.

INTERNATIONAL JOURNAL
of PEDIATRIC DERMATOLOGY

Special Issue, 2025
ISSN 3035-1006 online

Review

Redox Imbalance and the Skin: A Clinical Indicator of Hidden Systemic Risk

Michele Piazza[1], Carlo Capristo[2], Nunzia Maiello[2] and Attilio L. Boner[1]

[1]Pediatric Unit, Department of Surgical Sciences, Dentistry, Gynecology and Pediatrics, University of Verona, Verona, Italy; [2]Unit of Pediatrics, Department of Woman, Child and General and Specialized Surgery, University of Campania 'Luigi Vanvitelli', Naples, Italy

KEYWORDS

Oxidative stress
Skin diseases
Mitochondria
Autophagy
Redox imbalance
Antioxidant therapy
Multimodal supplementation
Atopic dermatitis
Psoriasis
Vitiligo
Chronic spontaneous urticaria
Endothelial dysfunction

CORRESPONDING AUTHOR

Attilio L. Boner,
Pediatric Unit,
Department of Surgical Sciences,
Dentistry, Gynecology and Pediatrics,
University of Verona,
Verona, Italy

e-mail: attilio.boner@univr.it

ABSTRACT

Oxidative stress (OxS) is a key pathological mechanism in many dermatologic and systemic disorders. As the largest and most exposed organ, the skin mirrors systemic redox imbalance and early signs of mitochondrial dysfunction, chronic inflammation, and immune dysregulation. This review examines the interplay between oxidative stress, mitochondrial damage, and impaired autophagy, highlighting their reflection in skin diseases and systemic comorbidities. Conditions such as atopic dermatitis, psoriasis, vitiligo, and chronic urticaria share oxidative and mitochondrial alterations that contribute to inflammation, premature aging, and cardiovascular or neurodegenerative risk. In atopic dermatitis, mitochondrial hyperactivity and defective autophagy connect barrier dysfunction with systemic vascular disease. The skin thus serves as a sentinel organ for redox imbalance. Evidence suggests that single, high-dose antioxidants may be ineffective or even pro-oxidant, while multi-antioxidant approaches—including vitamin D, folate, polyphenols, selenium, zinc, and magnesium—support mitochondrial resilience and immune balance. Recognizing cutaneous oxidative stress as both a biomarker and driver of systemic disease underscores the value of integrative antioxidant strategies for preventing and managing dermatologic and age-related disorders.

Copyright 2025 © by World Health Academy Publishing House
This publication and/or article is for individual use only and may not be further reproduced without written permission from the copyright holder.
Unauthorized reproduction may result in financial and other penalties
DISCLOSURE: ALL AUTHORS REPORT NO CONFLICTS OF INTEREST RELEVANT TO THIS ARTICLE.

Introduction

Oxidative stress (OxS) represents a critical pathological mechanism underlying various human diseases, including skin disorders. It arises from an imbalance between the generation of reactive oxygen species (ROS) and the biological system's ability to detoxify these reactive intermediates or repair the resulting damage. This damage is not random but primarily targets three major macromolecular classes: nucleic acids, proteins, and lipids (1).

ROS, such as hydroxyl radicals(•OH), readily attack DNA, causing base modifications, strand breaks, and crosslinking. Guanine, the DNA base with the lowest redox potential, is especially susceptible to oxidation, leading to the formation of 8-oxo-7,8-dihydroguanine (8-oxoG). This mutagenic lesion mispairs with adenine during replication, resulting in G→T transversions—a mutation pattern frequently observed in cancers (2).

Protein oxidation can result in fragmentation of peptide chains, partial loss of enzymatic activity, altered protein structure, and increased susceptibility to proteolytic degradation. Lipid peroxidation compromises membrane integrity and permeability, disrupts ion gradients and cellular homeostasis, and initiates apoptosis and necrosis (3). Each category of injury not only disrupts normal cellular functions but also contributes to pathological processes, including inflammation, carcinogenesis, and degenerative diseases.

The skin, being the largest and outermost organ of the body, is particularly vulnerable to oxidative insults. The objective of this report is to explore the interplay between oxidative stress and skin diseases, elucidate the molecular mechanisms involved, and evaluate potential preventive strategies, including antioxidants.

Skin mitochondria and oxidative stress

Mitochondria in skin cells play a dual role: they are essential for energy production but also serve as a significant source of ROS during electron transport. In skin tissues, mitochondrial dysfunction—often triggered by UV exposure or aging—results in excessive ROS production that damages cellular components, including mitochondrial DNA (mtDNA). This damage promotes a vicious cycle of mitochondrial decay and ROS overproduction, ultimately compromising cellular viability and tissue integrity (4).

Unlike nuclear DNA, mitochondrial DNA is not protected by histone proteins and is less efficiently repaired. ROS-induced mtDNA mutations have been implicated in dermal aging and various degenerative skin conditions. Accumulating evidence connects mitochondrial impairment with several dermatologic disorders, including cutaneous aging, hair loss, delayed wound healing, and inflammatory and autoimmune conditions such as systemic lupus erythematosus, psoriasis, atopic dermatitis, and vitiligo (4). Additionally, skin cancers associated with mutations in mitochondrial and nuclear genes regulating proliferation and apoptosis have been linked to mitochondrial dysfunction (5).

Excessive mitochondrial ROS can act as damage-associated molecular patterns (DAMPs), triggering "sterile inflammation" through pathways such as Toll-like receptor signaling (5). Chronic exposure to glucocorticoids, often used in skin disease therapy, may paradoxically aggravate oxidative stress by impairing mitochondrial function and enhancing ROS formation (6). This stress response has been associated with increased cell damage and premature senescence.

Skin autophagy and oxidative stress

Autophagy is a catabolic process that clears damaged organelles and macromolecules, playing a protective role against oxidative damage. Under oxidative stress, autophagy is upregulated to remove dysfunctional mitochondria (mitophagy), thereby preventing further ROS generation. This quality-control mechanism is crucial for maintaining mitochondrial health and skin vitality. However, chronic or excessive ROS exposure may impair autophagic flux, leading to the accumulation of damaged cellular components and inflammation (7). This impairment is observed in skin diseases such as psoriasis and atopic dermatitis, linking defective autophagy to disease pathogenesis.

Healthy skin function depends on the integrity of its barrier and immune defense. Autophagy is considered the "Guardian of the Skin Barrier" since it operates in various skin cell types, including keratinocytes and immune cells such as Langerhans cells, macrophages,

mast cells, neutrophils, NK cells, and T cells (8).

One of the critical consequences of reduced autophagy is the accumulation of senescent cells—referred to as "zombie cells"—which are metabolically active but non-dividing and resistant to apoptosis. These cells acquire a senescence-associated secretory phenotype (SASP) characterized by the secretion of inflammatory cytokines (e.g., IL-6), chemokines, growth factors, and matrix-degrading enzymes (9). This pro-inflammatory milieu contributes to tissue dysfunction and aging phenotypes. Thus, autophagy is essential for both epidermal renewal and immune surveillance.

Epigenetic effects of oxidative stress: corticosteroid resistance and allergic disease onset

OxS exerts a profound impact on the efficacy of corticosteroid therapy through altered glucocorticoid receptor (GR) isoform expression. While GR-α is the functional isoform responsible for transactivating anti-inflammatory genes via glucocorticoid response elements (GRE), OxS induces GR-β, a dominant-negative isoform that fails to bind corticosteroids and antagonizes GR-α function (10). This isoform switch contributes to steroid resistance, particularly in atopic dermatitis (11).

Furthermore, histone deacetylase-2 (HDAC2) plays a pivotal role in corticosteroid-mediated repression of pro-inflammatory gene transcription. Under oxidative stress, HDAC2 is inactivated via acetylation (12) impairing chromatin compaction and allowing open transcriptional access to pro-inflammatory genes such as thymic stromal lymphopoietin (TSLP). The net effect is an amplified inflammatory response and reduced sensitivity to corticosteroids, even in the presence of normal receptor levels. However, quercetin has been shown to impair TSLP expression, potentially counteracting this pro-inflammatory signaling pathway (13).

Recent evidence indicates that oxidative stress is not merely a byproduct of inflammation but may represent a prerequisite for the development of allergic diseases. Individuals or experimental models with an impaired ability to counteract oxidative stress—whether due to genetic, nutritional, or environmental factors—exhibit exaggerated responses to allergens. This includes overexpression of epithelial-derived cytokines or alarmins such as TSLP, which initiate and propagate Th2-driven immune responses (14). Experimental models, such as transgenic mice overexpressing TSLP in keratinocytes, demonstrate spontaneous development of eczema-like lesions, increased skin infiltration by Th2 cells, and elevated serum IgE in the absence of exogenous allergens (15). These findings underscore that oxidative stress-induced epithelial signaling alone is sufficient to trigger the atopic march, a progression from atopic dermatitis to allergic rhinitis and asthma. Moreover, oxidative stress disrupts immunometabolism and induces mitochondrial dysfunction, contributing to epigenetic alterations, especially in microRNA profiles, that further promote allergic sensitization and persistence (14). These changes act in concert to reprogram immune responses toward a pro-allergic phenotype, which cannot be counteracted by corticosteroids, as these drugs impair mitochondrial function (16, 17).

The recognition that oxidative stress undermines corticosteroid efficacy and facilitates allergy development highlights the importance of redox modulation in therapy. Antioxidants that restore HDAC2 activity and preserve GR-α function—such as quercetin, curcumin or polyphenolic compounds—have shown promise in preclinical models (13, 16) and it is biologically plausible that counteracting OxS may represent a viable strategy to prevent allergic sensitization and the onset of allergic diseases. In fact, strategies that bolster mitochondrial function or limit epithelial TSLP release may prevent allergic sensitization at its origin (13, 18).

The observation that oxidative stress impairs corticosteroid efficacy and promotes allergic disease underscores the therapeutic potential of redox modulation. Antioxidants that restore HDAC2 activity and preserve GR-α function—such as quercetin, curcumin, and other polyphenolic compounds—have shown promise in preclinical models (13, 16). Counteracting oxidative stress is therefore a biologically plausible strategy to prevent allergic sensitization and the development of allergic diseases. Moreover, approaches that enhance mitochondrial function or suppress epithelial TSLP release may help interrupt allergic sensitization at its origin.

Oxidative stress and aging: systemic and cutaneous perspectives

The free radical theory of aging, first proposed by Harman (19) and later expanded to include mitochondrial damage, posits that aging results from the accumulation of oxidative damage over time (20). Senescent cells often develop a senescence-associated secretory phenotype (SASP), releasing pro-inflammatory cytokines such as TNF-α, IL-1, IL-6, and IFN-γ, thereby contributing to inflammaging—a chronic, low-grade inflammation that accelerates aging and underlies many degenerative conditions (9). A crucial contributor to inflammaging is "macrophaging," where aged macrophages exhibit persistent activation and ROS production, overwhelming the anti-inflammatory regulatory systems, especially in elderly populations (21).

The skin, being constantly exposed to exogenous oxidative stressors such as UV radiation, pollutants, wind, and chemicals, is particularly susceptible to aging via ROS-dependent mechanisms. OxS impairs several key elements of skin architecture and function, including collagen degradation through activation of matrix metalloproteinases (MMPs), reduced collagen and elastin synthesis by fibroblasts, mitochondrial membrane damage and ATP depletion in skin cells, and increased epidermal thinning and wrinkling. ROS-mediated activation of NF-κB and MAPK pathways in keratinocytes and fibroblasts leads to overexpression of inflammatory mediators and proteolytic enzymes, compounding extracellular matrix (ECM) degradation (22). Moreover, advanced glycation end-products (AGEs), formed through nonenzymatic reactions between sugars and proteins or lipids, exacerbate skin aging (23). This process contributes to skin darkening, loss of elasticity, and links to systemic diseases such as diabetes and cataracts.

Hair aging exemplifies the visible outcomes of oxidative stress on ectodermal tissues. Major manifestations include greying (canities), associated with melanocyte apoptosis in the hair follicle bulb—likely driven by oxidative damage (24); androgenetic alopecia, linked to premature senescence of dermal papilla cells mediated by oxidative stress (25); and changes in hair fiber properties, where diameter, strength, and manageability are affected due to lipid peroxidation and matrix breakdown.

Early onset of hair aging phenomena is often observed in individuals with reduced antioxidant defenses (26), highlighting the critical protective role of endogenous redox regulation.

Oxidative stress is not merely a byproduct of aging but a driving force behind the molecular and cellular deterioration observed across tissues, with the skin being both a target and a model organ for studying redox-driven aging. Given the established role of oxidative stress in these degenerative changes, individuals showing clinical or histological signs of skin aging should be considered for intervention with a cascade of antioxidant molecules for healthy aging programming. Interventions aimed at enhancing antioxidant defenses, maintaining mitochondrial function, and modulating inflammatory signaling hold potential to slow aging and improve both skin and systemic health (13, 18).

Skin diseases and oxidative stress

Skin diseases represent a broad and heterogeneous group of conditions with increasing global prevalence, ranging from inflammatory disorders such as atopic dermatitis and psoriasis to autoimmune diseases, pigmentary disorders, premature aging, and malignancies. Despite their diversity, many skin diseases share a common pathogenic mechanism: the disruption of redox balance and the excessive generation of reactive oxygen species (ROS). When oxidative stress outweighs antioxidant capacity, it initiates a cascade of molecular events that fuel both the onset and progression of skin disorders (27).

Atopic Dermatitis: systemic oxidative stress and barrier dysfunction

Oxidative stress is a central pathogenic factor in atopic dermatitis (28). Higher urinary oxidative biomarkers correlate with SCORAD scores and disease severity (29). ROS levels are elevated both locally in the skin and systemically, leading to cellular and tissue damage. Studies reveal elevated malondialdehyde (MDA) and decreased enzymatic antioxidants (SOD, catalase, GPx) and non-enzymatic antioxidants (glutathione, vitamins A, C, and E) in AD patients' blood (30). Increased urinary markers of oxidative DNA damage such as 8-OHdG and pentosidine correlate with disease severity and risk of progression to asthma and allergic rhinitis (31). Markers of oxidative stress are elevated in the exhaled air of children with AD (32).

Such findings underscore that oxidative stress in AD is not merely local but reflects a systemic pro-oxidative state, even detectable in the respiratory tract. This supports the growing concept of atopic diseases as a multi-organ oxidative-inflammatory syndrome, where the skin-lung axis may be modulated by common redox-sensitive pathways.

Enhanced oxidative stress is observed even in non-lesional skin, suggesting a pre-activated disease state (33). Keratinocytes in atopic AD exhibit mitochondrial hyperactivity, characterized by increased fatty acid oxidation, elevated ROS production—particularly hydrogen peroxide (H_2O_2)—and enhanced mitochondrial proton leak, highlighting the pathological role of mitochondria even in non-lesional skin (33). In this study, although the antioxidative stress response was upregulated, it appeared insufficient to prevent reactive oxygen species (ROS)-mediated deleterious effects such as lipid peroxidation and DNA damage. The high production of ROS can induce autophagy, apoptosis and programmed necrosis in cells, resulting in DNA damage and skin barrier breakdown (34). In mouse models (e.g., flaky tail mice), this mitochondrial overproduction of H_2O_2 contributes to skin inflammation and barrier disruption. Targeting this dysfunction with mitochondria-specific antioxidants such as MitoQ has been shown to reduce inflammation and restore homeostasis (35). Oxidative stress contributes directly to downregulation of skin barrier proteins and to enhanced colonization by Staphylococcus aureus, which fuels inflammation and perpetuates the cycle of oxidative stress, immune activation, and barrier impairment (36).

AD skin shows reduced expression of NRF2, a master regulator of antioxidant defense and epidermal homeostasis. Proteomic analyses reveal decreased NRF2 activity, lower levels of mitochondrial proteins, and impaired detoxification responses (37). In fact, restoring NRF2 activity via NRF2-activating compounds (e.g., curcumin, quercetin, resveratrol) is emerging as a promising therapeutic strategy (38, 39). Supplementation with zinc shows beneficial effects on inflammation, pruritus, and barrier repair (40). Topical and systemic curcumin has been shown to downregulate TSLP expression, suppress STAT6 and GATA-3, normalize epidermal thickness, and inhibit the progression of the atopic march in experimental models (41).

Given the strong role of oxidative stress in AD, a multimodal antioxidant approach is warranted. This includes topical antioxidants (e.g., MitoQ, curcumin), systemic supplementation (zinc, selenium, vitamin E, vitamin D, polyphenols) (42) and bath therapy using mineral-rich salts (e.g., sodium chloride, magnesium, allantoin, urea) (43) to reduce inflammation, oxidative load and restore skin hydration. These strategies can break the cycle of oxidative damage, immune activation, and barrier dysfunction, ultimately improving patient outcomes.

Acne Vulgaris: oxidative stress as an initiating pathogenic event

Acne vulgaris is a chronic inflammatory condition of the pilosebaceous unit and is now recognized as being strongly influenced by oxidative stress (44). Recent evidence indicates that oxidative stress may represent the initiating event (45) not just a secondary phenomenon, since malfunctioning follicular walls and altered sebum composition promote local ROS production, especially superoxide (O_2^-) and hydrogen peroxide (H_2O_2). ROS activate toll-like receptor 2 (TLR2), triggering a cascade of pro-inflammatory cytokines (IL-1β, IL-8, TNF-α), thereby amplifying the inflammatory response (46).

A meta-analysis involving 14 trials and over 1,000 participants confirmed increased malondialdehyde (MDA) levels and reduced superoxide dismutase (SOD) and total antioxidant capacity (TAC) in patients compared to healthy subjects, with a clear association between MDA levels and acne severity (44). Additionally, systemic markers such as oxidized DNA, nitric oxide species, and depleted glutathione have been reported in plasma and lesion scrapings.

Besides antibiotics such as tetracycline and erythromycin, which also act by reducing H_2O_2 levels (47), antioxidant therapies using zinc, selenium, curcumin, resveratrol, and folic acid have demonstrated beneficial effects in modulating redox imbalance and improving metabolic parameters, especially in individuals with acne linked to metabolic syndrome (44). While isotretinoin remains the gold standard, it paradoxically increases oxidative stress, often requiring antioxidant supplementation to mitigate systemic side effects (48).

Psoriasis: mitochondrial oxidative stress and chronic immune activation

Extensive data link oxidative stress with both the onset and severity of psoriasis. A 2019 meta-analysis revealed that patients with psoriasis had lower total antioxidant status (TAS), higher total oxidant status (TOS), increased levels of MDA, and decreased catalase activity compared to controls (49). Psoriatic lesions show elevated mitochondrial ROS (mtROS) production and mitochondrial ROS are essential for the development of psoriatic inflammation (50). In the serum of these patients, mitochondrial DNA (mtDNA) is found in oxidized form, reflecting systemic oxidative stress. These changes activate inflammatory cascades via dendritic cell stimulation, MAPK phosphorylation, and NF-κB signaling (51).

In mouse models, mitoquinone (MitoQ), a mitochondria-targeted antioxidant, was effective in reducing psoriatic inflammation (47). Psoriasis patients exhibit oxidative and epigenetic damage to blood DNA, particularly 8-hydroxy-2′-deoxyguanosine, indicating widespread nuclear damage (52). Shortened telomeres in T cells ($CD8^+CD28^+$) suggest chronic immune stimulation and increased turnover, consistent with accelerated immune aging in both patients with psoriasis and atopic dermatitis (53).

Antioxidants such as curcumin (including Meriva and nanocurcumin formulations) improve psoriasis severity index scores and modulate lipid profiles when combined with retinoids (e.g., acitretin) (54, 55). Curcumin also reduces serum IL-22, a cytokine linked to psoriasis pathogenesis (56). Topical or oral vitamin D analogues (e.g., calcipotriol) also function indirectly by inhibiting phosphorylase kinase, which is redox-sensitive and linked to lesion resolution (50).

Chronic Spontaneous Urticaria: a critical pathogenic driver

Emerging evidence highlights OxS as a critical and underrecognized contributor to chronic spontaneous urticaria (CSU) persistence, severity, and treatment resistance (57). Multiple studies have demonstrated that patients with CSU exhibit significantly higher systemic oxidative stress compared to healthy controls (58, 59). This is characterized by increased markers of lipid peroxidation, such as elevated malondialdehyde (MDA) levels in serum and platelets, alongside reduced antioxidant enzyme activity—notably superoxide dismutase (SOD) and glutathione peroxidase (GPx) (60). Additionally, patients show lower total antioxidant status (TAS) and elevated total oxidant status (TOS) in plasma, resulting in a significantly higher oxidative stress index (OSI) (58-60).

Importantly, there is a positive correlation between TOS/OSI and the urticaria activity score (UAS7), suggesting that oxidative stress intensity directly relates to disease activity ($\rho = 0.381$ and $\rho = 0.337$, respectively; $p < 0.01$) (59). Children with CSU also demonstrate elevated nitrosative stress, with significantly increased serum nitrite and total nitric oxide (NOx) metabolites that positively correlate with UAS7 scores. Nitric oxide (NO), as a reactive nitrogen species, functions not only as a vasodilator but also enhances vascular permeability, further aggravating dermal edema and wheal formation (59).

Advanced oxidative stress markers, including advanced glycation end products (AGEs) and advanced oxidation protein products (AOPPs), are significantly elevated in CSU patients (55). These markers reflect oxidative modification of circulating and tissue proteins, particularly albumin, and are linked with chronic inflammation and immune dysregulation. Notably, these markers remain uninfluenced by autologous serum/plasma test positivity, suggesting they reflect a fundamental metabolic disturbance in CSU.

Activated platelets from CSU patients demonstrate a particularly interesting pathophysiological profile. They contain significantly elevated MDA levels, show decreased SOD and GPx activity, and release increased levels of pro-inflammatory cytokines, including IL-6 and high-sensitivity CRP (59). This evidence suggests that platelets function as active sources of reactive oxygen species (ROS) and inflammatory mediators, contributing to the prothrombotic and inflammatory state characteristic of CSU (61).

Gene expression profiling from lesional skin of CSU patients reveals upregulation of oxidative stress-related genes and increased expression of vascularization markers such as CYR61. The normalization of these gene expression signatures following omalizumab treatment, which corresponds with clinical improvement, provides compelling evidence for the therapeutic relevance of targeting oxidative pathways (62).

These findings collectively demonstrate that oxidative stress operates not only systemically but also manifests locally in skin lesions, providing a molecular basis for the persistent cutaneous manifestations observed in CSU. Therefore, oxidative stress emerges as a major

pathogenic driver in chronic spontaneous urticaria, influencing disease activity, inflammation, vascular permeability, and treatment responsiveness.

Given the central involvement of reactive oxygen species (ROS) and reactive nitrogen species (RNS), antioxidant-based therapies represent a promising therapeutic avenue. These may include nutritional supplementation, targeted pharmacological agents, or immune modulation strategies such as omalizumab, all of which may offer significant benefits in CSU management. This perspective becomes particularly relevant considering that nearly half of patients with CSU do not respond adequately to antihistamines, highlighting the need for alternative therapeutic strategies (63). Future therapeutic approaches should therefore consider redox modulation as an integral component of personalized treatment strategies in CSU

Vitiligo: mitochondrial oxidative stress and melanocyte dysfunction

Vitiligo is a complex skin disorder characterized by melanocyte dysfunction and death, leading to depigmented patches. A central mechanism in its pathogenesis is oxidative stress, particularly mitochondria-derived ROS overproduction (64).

Mitochondrial dysfunction in vitiligo is marked by altered electron transport chain (ETC) activity, increased proton leak, and reduced ATP synthesis, especially in peri-lesional skin. The accumulation of hydrogen peroxide (H_2O_2) and impaired antioxidant defenses induce melanocyte apoptosis via the TRPM2 channel, which mediates Ca^{2+}-dependent mitochondrial cell death (65, 66). Morphological changes in mitochondria, including cristae abnormalities, are evident alongside elevated mitochondrial ROS levels that can reach up to 257% higher in peri-lesional melanocytes compared to healthy controls (66).

Meta-analyses confirm increased malondialdehyde (MDA) and lipid peroxidation in blood and erythrocytes of vitiligo patients, highlighting a systemic oxidative phenotype (67). These data strongly indicate that oxidative stress acts as both an initiator and amplifier of vitiligo pathology, directly impairing melanocyte function and survival while driving immune-mediated secondary damage.

Systemic Lupus Erythematosus: oxidative stress and autoimmune amplification

Systemic Lupus Erythematosus (SLE) is a multisystem autoimmune disease with common skin involvement and a well-established oxidative pathophysiological profile (68). Mitochondria in lupus patients exhibit excessive ROS production, dysfunctional antioxidant enzymes, and mitochondrial DNA (mtDNA) oxidation (69). Oxidized mtDNA is released into the cytosol, where it activates the cGAS-STING pathway, inducing type I interferon-stimulated genes (ISGs) and amplifying autoimmunity. Chronic oxidative phosphorylation dysfunction in immune cells drives sustained inflammation, autoantibody production, and tissue damage. Nrf2, a key antioxidant transcription factor, is underactive in SLE, and Nrf2-activating compounds are emerging as novel therapeutic strategies, particularly for lupus nephritis (70).

Melanoma: the double-edged role of oxidative stress

Melanoma arises from melanocytes, which naturally maintain high ROS levels due to melanin synthesis (71). This redox activity represents both a protective and pathogenic factor in melanocyte biology. Melanin synthesis, particularly pheomelanin production, generates substantial ROS and can promote DNA damage and carcinogenesis, especially under UV exposure (72). OxS leads to global DNA hypomethylation, genomic instability, and oncogene activation in melanocytes (73). Melanoma progression is associated with increased lipid peroxidation, as evidenced by elevated malondialdehyde (MDA) levels in serum, confirming systemic oxidative imbalance that correlates with tumor stage (74).

Nrf2 plays a particularly complex dual role in melanoma pathogenesis: it functions protectively in early melanocyte homeostasis and UV defense, but becomes tumor-promoting in established melanoma, where it helps cancer cells maintain redox balance, resist therapy, and facilitate metastasis (75, 76). This paradoxical role highlights the importance of context-dependent redox signaling in cancer biology.

Therapeutic approaches targeting this oxidative vulnerability show promise. Agents like naringenin, derived from citrus fruits, demonstrate potential in selectively inducing ROS-mediated apoptosis in melanoma

cells (77). In melanoma, oxidative stress represents a double-edged sword—promoting initial transformation and progression while simultaneously providing exploitable vulnerabilities for therapeutic targeting through pro-oxidant drugs and redox modulation strategies.

Wound Healing: balancing beneficial and harmful ROS effects

ROS play a biphasic role in wound healing, proving essential at low concentrations yet deleterious when present in excess (78). During acute wound repair, ROS provide beneficial functions including antimicrobial activity, cell signaling facilitation, angiogenesis promotion, and matrix remodeling support.

In contrast, chronic wounds such as diabetic foot ulcers are characterized by persistent oxidative stress, mitochondrial dysfunction, and failure of redox homeostasis (79). This oxidative imbalance disrupts all phases of healing, from initial inflammation through final tissue remodeling. ROS overproduction damages endothelial cells, fibroblasts, and keratinocytes, promoting tissue breakdown rather than facilitating repair processes.

Therapeutic interventions targeting oxidative stress have shown clinical promise (80). Nutraceuticals like curcumin improve wound healing outcomes by reducing systemic oxidative markers such as MDA and CRP, improving endothelial function and flow-mediated dilation, and modulating insulin resistance and inflammatory cytokine profiles (81).

These findings demonstrate that while controlled ROS generation is vital for successful acute wound healing, excessive oxidative stress serves as a major driver of chronic non-healing wounds. Antioxidant therapies, including curcumin supplementation, represent effective adjunctive treatments to promote tissue regeneration and restore normal healing processes.

Skin Infectious Diseases: the dual role of oxidative stress in host defense

Oxidative stress (OxS) plays a dual and context-dependent role in skin infectious diseases. On one hand, reactive oxygen species (ROS) are critical for host defense, enabling the immune system to eliminate pathogens effectively. On the other hand, uncontrolled ROS production can cause collateral damage to host tissues, aggravate inflammation, and impair healing processes (27). Skin, serving as the primary barrier against environmental insults, represents a critical site where this delicate balance is frequently challenged.

ROS in Innate Immune Response and Pathogen Control

During infection, neutrophils, macrophages, and keratinocytes produce ROS via NADPH oxidase and mitochondrial pathways as part of the innate immune response. These ROS serve multiple protective functions: eliminating invading bacteria, viruses, and fungi; regulating inflammatory responses; and activating signaling pathways that stimulate antimicrobial peptide production and cytokine release. However, excessive ROS production can lead to tissue damage, prolonged infection, and delayed resolution by damaging DNA, proteins, and lipids in skin cells, disrupting skin barrier function, and inducing apoptosis or necrosis of keratinocytes (82).

Bacterial Infections and Oxidative Imbalance

Staphylococcus aureus infections exemplify this dual role of oxidative stress. S. aureus activates Toll-like receptors (TLRs) on keratinocytes, triggering ROS production that participates in pathogen elimination. However, S. aureus superantigens and toxins can amplify ROS formation beyond protective levels, causing epidermal damage and promoting chronic inflammation (83). Biofilm formation further exacerbates oxidative imbalance by shielding bacteria from host defenses while sustaining prolonged inflammatory responses (84).

Viral Infections and Redox Dysregulation

Viral pathogens such as herpes simplex virus (HSV) induce significant oxidative stress during replication. ROS are generated in both infected keratinocytes and responding immune cells, and this oxidative stress contributes to viral reactivation, skin lesion formation, and impaired antiviral immunity (85). In these clinical contexts, antioxidant interventions can reduce viral load and symptom severity by modulating redox-sensitive signaling pathways (86).

Fungal and Parasitic Infections

Pathogens including Candida albicans and dermatophytes are similarly influenced by host ROS responses, which have been shown to induce biofilm formation (87). While ROS help contain fungal spread initially, chronic fungal infections can lead to excessive ROS accumulation and tissue damage. In cutaneous leishmaniasis, oxidative stress demonstrates a particularly complex dual role: beneficial through parasite-killing mechanisms, yet harmful by contributing to tissue ulceration and delayed healing processes (88).

Therapeutic Implications and Future Directions

A deeper understanding of redox biology in skin infections offers significant opportunities to develop adjunctive therapies that not only combat infection effectively but also preserve skin integrity and accelerate recovery. Such approaches could optimize the protective functions of ROS while minimizing their detrimental effects on host tissues.

Skin diseases as a "canary in the mine": a sentinel for oxidative and inflammatory dysregulation

1. The skin as a sentinel organ

The skin, being the largest and most exposed organ of the human body, is uniquely positioned to reflect internal physiological disturbances, including those related to climatic changes and environmental pollution (89). Just as a canary in a coal mine warns of invisible toxic gases, skin diseases often precede or co-occur with deeper systemic disorders, acting as an early and visible alert for underlying OxS and chronic low-grade inflammation (90).

2. Early dermatological signs of systemic dysfunction

i) Skin Aging as a Mortality Predictor

Skin aging and wrinkles can be considered mortality predictors with significant clinical implications. A longitudinal study in French workers demonstrated that forehead wrinkles were significantly associated with cardiovascular mortality, independent of age or classical risk factors. Subjects with the deepest wrinkles had a 6-fold higher risk of death compared to those without wrinkles (91). These findings suggest that cutaneous changes—such as collagen degradation and oxidative damage—can mirror vascular and metabolic aging processes throughout the body.

ii) Hair Changes as Cardiometabolic Warnings

Hair graying and baldness should be considered important cardiometabolic warning signs. Hair graying is linked to melanocyte apoptosis caused by ROS, making it a visible marker of oxidative tissue injury. Androgenetic alopecia correlates with cardiovascular risk, including hypertension and coronary artery disease, as evidenced by data from the Framingham Heart Study (92).

3. Cutaneous diseases and systemic inflammation

i) Atopic Dermatitis, Systemic Inflammation, and Degenerative Comorbidities

Atopic dermatitis (AD) is associated not only with atopic conditions but also with a heightened risk of cardiovascular disease (93), mental illness (94) and autoimmune disorders (95). Mechanistically, this association is driven by mitochondrial oxidative dysfunction, endothelial activation, and platelet hyperactivity, forming a nexus of systemic inflammation and vascular risk (93). A comprehensive UK study involving 3.6 million people demonstrated increased hazard ratios for stroke, myocardial infarction, and heart failure in individuals

with AD (96). Moreover, recent evidence suggests that adults with atopic dermatitis may also have a higher susceptibility to age-related macular degeneration (97). Both conditions share features of impaired autophagy and oxidative stress–driven barrier dysfunction, leading to chronic inflammation and tissue degeneration (8). This mechanistic overlap supports the view of AD as a systemic disorder extending beyond the skin, with redox imbalance and defective cellular clearance processes contributing to multiple age-related pathologies.

ii) Psoriasis and Systemic Immune Activation.

Psoriasis is characterized by systemic immune activation, oxidative DNA damage, and vascular stiffening (98, 99). It demonstrates strong associations with metabolic syndrome, autoimmune conditions, and premature aging in relation to endothelial dysfunction (100). The disease reflects ongoing mitochondrial stress and inflammaging processes, even in younger patients. Epidemiological studies have shown that the incidence of cognitive impairment, including dementia and Alzheimer's disease, is higher in subjects with certain inflammatory skin disorders, including psoriasis and chronic eczematous dermatitis (101). Because of the pathogenic role of epidermal dysfunction in ageing-associated cutaneous inflammation, improvements in epidermal function could be an alternative approach for mitigation of the ageing-associated decline in cognitive function.

iii) Vitiligo and Systemic Complications.

Vitiligo, traditionally viewed as a localized skin depigmentation disorder, is now recognized as being associated with sensorineural hearing loss (102), cardiovascular disease (103) and metabolic syndrome (104)—all conditions with a foundation in oxidative stress and systemic immune imbalance.

iv) Chronic spontaneous urticaria (CSU) and autoimmunity.

CSU is increasingly recognized to co-occur with various autoimmune conditions. Among these, autoimmune thyroid diseases, particularly Hashimoto's thyroiditis and hypothyroidism, have been prominently associated with CSU even in the absence of overt thyroid disease symptoms (105). This comorbidity underscores the importance of screening CSU patients for thyroid function and autoantibody levels, particularly in cases of treatment resistance or persistent urticaria.

v) Oxidative Stress and Metabolic Syndrome as Shared Pathogenic Mechanisms in Acne Vulgaris.

Recent evidence highlights a significant link between acne vulgaris and metabolic syndrome (106), a cluster of conditions including obesity, insulin resistance, hypertension, and dyslipidemia. This association suggests shared pathophysiological mechanisms primarily involving oxidative stress and systemic inflammation qui c'era 106 errore (106) (45).

4. Health programming implications

Given the pathogenic role of epidermal dysfunction in aging-associated cutaneous inflammation, improving epidermal function may represent a complementary strategy for mitigating the progression of aging-related non-communicable diseases (101). However, skin health should not be addressed in isolation. Given the wealth of data linking cutaneous changes to systemic pathology, dermatological symptoms should be viewed as windows into internal health rather than isolated cosmetic concerns. In this context, good care of the skin should be implemented alongside strategies aimed at managing oxidative stress. Physicians should adopt a 'redox-aware' perspective, whereby visible skin alterations prompt a comprehensive evaluation of oxidative load, metabolic function, and inflammatory status.
Evidence from a study in obese children indicates that vitamin D, folic acid, curcumin, resveratrol, zinc, selenium and magnesium supplementation improve endothelial dysfunction. Based on these findings, it is plausible that these antioxidants may also contribute to improved skin conditions and reduced cardiometabolic risk (107). Furthermore, incorporating redox and inflammatory screening into dermatologic evaluations may offer powerful opportunities for early intervention, preventive care, and health optimization strategies.
The different skin-related conditions and their associated systemic risk events are summarized in Table I.

Table I. *Skin diseases and their associated systemic consequences.*

Skin Disease / Condition	Associated Systemic Consequences	Mechanisms / Notes
Skin Aging (Wrinkles)	Cardiovascular mortality	Forehead wrinkles linked to 6x increased risk of death; reflect vascular and metabolic aging via collagen degradation and OxS.
Hair Graying & Baldness	Cardiometabolic risk (hypertension, coronary artery disease)	ROS-induced melanocyte apoptosis; androgenetic alopecia linked to CVD risk.
Atopic Dermatitis (AD)	Cardiovascular disease, mental illness (including dementia) and autoimmune disorders	Driven by mitochondrial oxidative dysfunction, endothelial activation, and platelet hyperactivity.
Psoriasis	Metabolic syndrome, autoimmune diseases, premature vascular aging, cognitive impairment	Systemic immune activation, oxidative DNA damage, vascular stiffening, inflammaging, and mitochondrial stress.
Vitiligo	Sensorineural hearing loss, cardiovascular disease, metabolic syndrome	Associated with oxidative stress and systemic immune imbalance.
Chronic Spontaneous Urticaria (CSU)	Autoimmune thyroid disorders (especially Hashimoto's thyroiditis and hypothyroidism)	High co-occurrence even without overt thyroid symptoms; immune dysregulation mechanism.
Acne Vulgaris	Metabolic syndrome (obesity, insulin resistance, hypertension, dyslipidemia)	Shared mechanisms involve chronic inflammation and oxidative stress.

Multicomponent antioxidant strategies: beyond single-molecule interventions

The limitations of monotherapy

Large clinical trials using high-dose vitamin C or E—the so-called "non-selective antioxidant therapies"—have failed to show significant benefit in major diseases such as cardiovascular disease or chronic inflammatory conditions (108, 109). This failure reflects a critical issue: OxS is not a single-pathway disturbance, and therefore, its mitigation cannot rely on a single antioxidant compound.

Monotherapies often lack pleiotropic effects, meaning they fail to address multiple mechanisms of action simultaneously. High-dose single antioxidants can even become pro-oxidant under certain metabolic conditions. Trials such as EPIC-Norfolk highlight that dietary source of antioxidants from fruits and vegetables are more beneficial than isolated supplement forms (110). The advantages of multi-component supplementation are exemplified by what occurs naturally with a diet rich in fruits and vegetables. Just as in nature there is never an isolated substance - when we eat an apple, we don't just consume quercetin, but a harmonious ensemble of nutrients that enhance each other - this principle should guide antioxidant supplementation with multiple molecules with different and synergic effects as shown in Table II (111). Micronutrient deficiencies do not occur in isolation (112) and an approach optimizing multiple micronutrients may have significant short- and even long-term benefits (113).

Table II. *Biological effects of different nutritional components.*

Effect/Substances	Folic acid	Vitamin C	Vitamin D	Vitamin E	Magnesium	Selenium	Zinc	Phytochemicals
Antiviral activity			✓		✓	✓	✓	✓
Immune modulation	✓	✓	✓	✓	✓	✓	✓	✓
Anti-inflammatory	✓	✓	✓	✓	✓	✓	✓	✓
Auto immunity prevention		?	✓	?	?	✓	✓	✓
Antioxidant effect	✓	✓	✓	✓	✓	✓	✓	✓
Anti-thrombotic effect	✓		✓	✓	✓	✓		✓
Endothelial protective	✓	✓	✓	✓	✓	✓	✓	✓
Cytoprotective & organ damage prevention	✓		✓	✓	✓	✓		✓
Antiarrhythmic effect			✓		✓	?		✓
Antidepression effect	✓		✓		?	?	✓	✓
Microbiome	✓		✓	✓		?	?	✓

Based on the comparative analysis of micronutrient functions, Vitamin D and phytochemicals (particularly polyphenols) emerge as the only compounds demonstrating activity across all evaluated domains. Notably, a combined supplementation strategy involving also vitamin E, selenium, magnesium, and zinc appears to cover nearly all functional targets when considered together.

The case for multimodal antioxidant therapy

Oxidative stress is intimately linked to a network of biological processes, including inflammation, autoimmunity, endothelial dysfunction, platelet activation, and mitochondrial damage. Therefore, a successful antioxidant approach should address all these dimensions simultaneously. This concept is supported by data from both experimental and clinical studies, which demonstrate that combinations of micronutrients and phytochemicals are significantly more effective than individual agents (114-123).

The following compounds demonstrate antioxidant, anti-inflammatory, immune-regulatory, and vascular-protective effects, as detailed in Table III.

Table III. *Micronutrients with Documented Multilevel Effects.*

Molecule	Documented Actions
Curcumin	Antioxidant, anti-inflammatory, anti-IL-1β/IL-6, endothelial protection
Resveratrol	ROS scavenger, mitochondrial support, platelet aggregation inhibitor
Zinc	Supports immune function, antioxidant enzyme cofactor (e.g., SOD), antiviral
Magnesium	Modulates oxidative metabolism, smooth muscle tone, endothelial function
Selenium	Integral for GPx activity, immune support, redox homeostasis
Vitamin D	Immune regulation, inflammation control, telomere stabilization
Folic Acid	Methylation supports endothelial health, reduces homocysteine
Vitamin E	Lipid membrane antioxidant, suppresses MDA generation
Quercetin	Flavonoid with anti-inflammatory and mast cell stabilizing effects
Melatonin	Antioxidant, anti-tumor, circadian regulator
Eucalyptus Oil	Topical antioxidant, antimicrobial, insect repellent

Each of these compounds addresses different facets of oxidative damage and immune dysfunction.

Clinical and experimental evidence supporting combination therapy

Studies in elderly populations demonstrate that multivitamin and multimineral supplementation improves immune responses, reduces infection risk, and lowers systemic inflammation (124-126). The OBELIX study provided compelling evidence that a formulation including curcumin, resveratrol, zinc, selenium, magnesium, vitamin D, and folic acid significantly improved endothelial function in obese pediatric patients over six months (107). Supplementation was associated with improved hyperemic response and endothelial function.

Broader health implications

Multicomponent antioxidant strategies are not only beneficial for dermatological health (127) but are also increasingly recognized for their roles in preventing autoimmune progression, modulating platelet activity, slowing telomere attrition, and supporting healthy aging processes (128).

Effective antioxidants must not only neutralize ROS but also block inflammatory cytokine cascades (e.g., IL-6, TNF-α, IL-17A), protect endothelial and mitochondrial integrity, and modulate immune tolerance to prevent overactivation (129, 130). This comprehensive approach addresses the multifaceted nature of oxidative stress and its systemic consequences.

High-dose supplementation with single antioxidants such as vitamin E or β-carotene has been associated with paradoxical pro-oxidant effects, sometimes increasing oxidative stress and all-cause mortality rather than reducing it. This phenomenon, described by Miller et al. (131) and Halliwell (132), arises because reactive oxygen species (ROS) are not solely deleterious; they play essential roles in redox signaling, immune defense, and metabolic adaptation. Excessive quenching of ROS can therefore disrupt physiological signaling and redox balance.

Several antioxidants can switch from antioxidant to pro-oxidant activity under specific conditions—for instance, vitamin E in the absence of recycling cofactors or vitamin C in the presence of transition metals—thus propagating rather than preventing lipid oxidation. Furthermore, biological compartmentalization of oxidative processes limits the efficacy of single compounds. Oxidative reactions occur heterogeneously within cells, as different organelles and microenvironments produce and neutralize ROS distinctly. Each antioxidant has a preferred site of action depending on its solubility, molecular size, charge, and redox potential—for example, polyphenols act in the cytosol while vitamin E protects lipid membranes. By supporting glutathione peroxidase, superoxide dismutase, and other redox enzymes, selenium, zinc, and magnesium help maintain mitochondrial integrity, limit ROS accumulation, and sustain efficient oxidative phosphorylation (133).

Conversely, multi-antioxidant supplementation that includes vitamin D, folic acid, polyphenols, selenium, and trace elements provides broader protection through complementary mechanisms. Folic acid supports redox equilibrium by reducing homocysteine accumulation and enhancing glutathione regeneration, while vitamin

D modulates Nrf2-dependent antioxidant enzymes and suppresses NF-κB–mediated inflammation. This integrated approach promotes a balanced oxidative–inflammatory response and minimizes the risk of pro-oxidant conversion observed with isolated antioxidants at high doses (134).

Conclusions

The evidence reviewed underscores oxidative stress as a central pathogenic mechanism in a broad spectrum of skin disorders, including chronic spontaneous urticaria, atopic dermatitis, melanoma, and impaired wound healing. Beyond its dermatological manifestations, the skin's role as a sentinel organ positions it as a valuable indicator of systemic redox and inflammatory imbalance, offering an accessible window for early intervention.

Addressing oxidative stress in skin diseases requires more than symptomatic relief—it calls for a comprehensive strategy to restore redox homeostasis. Approaches involving antioxidant therapy, nutraceuticals, and mitochondrial support not only improve clinical symptoms but may also alter disease trajectories. Single-molecule interventions are inadequate in the face of complex redox dysregulation; instead, a layered, multi-targeted approach—integrating antioxidants, anti-inflammatories, mitochondrial protectors, and immunomodulators—is essential to achieve sustained clinical benefit. This paradigm aligns with the multifaceted biology of oxidative stress and its shared contribution to dermatological, metabolic, cardiovascular, and neurodegenerative conditions.

Notably, recent longitudinal multi-omics studies reveal that biological aging follows a nonlinear path, with inflection points around 44 and 60 years marking critical shifts in mitochondrial, immune, and metabolic function (135). These critical transitions correspond to shifts in major biological processes, with the first crest (~44 years) associated with perturbations in cardiovascular function, lipid and alcohol metabolism, and mitochondrial homeostasis, and the second (~60 years) linked to dysregulation in immune responses and carbohydrate metabolism. These findings advocate flexible, age-adapted interventions that reinforce mitochondrial resilience and immune-metabolic stability.

Moreover, with evidence suggesting that nearly half of dementia cases could be prevented through optimal vascular health maintenance in later life, redox management emerges as a powerful, system-wide tool (136). It holds promise not only for skin health but also for delaying or preventing cognitive decline and mitigating the burden of cardiovascular and metabolic diseases. As redox biology continues to evolve, personalized, integrative antioxidant strategies represent a frontier with wide-reaching clinical implications—supporting not just dermatological outcomes but also contributing to the broader pursuit of healthy aging and chronic disease prevention. In this context, skin diseases may serve as a "canary in the mine," offering early signals that guide the implementation of optimal, comprehensive antioxidant treatment strategies.

References

1. Sies H. Oxidative stress: a concept in redox biology and medicine. Redox Biol. 2015;4:180-3.
2. Vasquez CA, Osgood NRB, Zepeda MU, Sandel DK, Cowan QT, Peiris MN, et al. Precision genome editing and in-cell measurements of oxidative DNA damage repair enable functional and mechanistic characterization of cancer-associated MUTYH variants. Nucleic Acids Res. 2025;53.
3. Sies H, Berndt C, Jones DP. Oxidative Stress. Annu Rev Biochem. 2017;86:715-48.
4. Natarelli N, Gahoonia N, Aflatooni S, Bhatia S, Sivamani RK. Dermatologic Manifestations of Mitochondrial Dysfunction: A Review of the Literature. Int J Mol Sci. 2024;25.
5. Wenzel P, Kossmann S, Münzel T, Daiber A. Redox regulation of cardiovascular inflammation - Immunomodulatory function of mitochondrial and Nox-derived reactive oxygen and nitrogen species. Free Radic Biol Med. 2017;109:48-60.
6. Bhattacharya A, Chakraborty M, Chanda A, Alqahtani T, Kumer A, Dhara B, et al. Neuroendocrine and cellular mechanisms in stress resilience: From hormonal influence in the CNS to mitochondrial dysfunction and oxidative stress. J Cell Mol Med. 2024;28:e18220.
7. D'Arcy MS. Cell death: a review of the major forms of apoptosis, necrosis and autophagy. Cell Biol Int. 2019;43:582-92.
8. Kim HJ, Park J, Kim SK, Park H, Kim JE, Lee

S. Autophagy: Guardian of Skin Barrier. Biomedicines. 2022;10.
9. Wang B, Han J, Elisseeff JH, Demaria M. The senescence-associated secretory phenotype and its physiological and pathological implications. Nat Rev Mol Cell Biol. 2024;25:958-78.
10. Oakley RH, Jewell CM, Yudt MR, Bofetiado DM, Cidlowski JA. The dominant negative activity of the human glucocorticoid receptor beta isoform. Specificity and mechanisms of action. J Biol Chem. 1999;274:27857-66.
11. Clayton MH, Leung DY, Surs W, Szefler SJ. Altered glucocorticoid receptor binding in atopic dermatitis. J Allergy Clin Immunol. 1995;96:421-3.
12. Osoata GO, Yamamura S, Ito M, Vuppusetty C, Adcock IM, Barnes PJ, et al. Nitration of distinct tyrosine residues causes inactivation of histone deacetylase 2. Biochem Biophys Res Commun. 2009;384:366-71.
13. Beken B, Serttas R, Yazicioglu M, Turkekul K, Erdogan S. Quercetin Improves Inflammation, Oxidative Stress, and Impaired Wound Healing in Atopic Dermatitis Model of Human Keratinocytes. Pediatr Allergy Immunol Pulmonol. 2020;33:69-79.
14. Hussain SA, Grayson MH. Chronic allergy signaling: is it all stressed-out mitochondria? Fac Rev. 2022;11:37.
15. Yoo J, Omori M, Gyarmati D, Zhou B, Aye T, Brewer A, et al. Spontaneous atopic dermatitis in mice expressing an inducible thymic stromal lymphopoietin transgene specifically in the skin. J Exp Med. 2005;202:541-9.
16. Kerppola W. Uncoupling of the oxidative phosphorylation with cortisone in liver mitochondria. Endocrinology. 1960;67:252-63.
17. Kimberg DV, Loud AV, Wiener J. Cortisone-induced alterations in mitochondrial function and structure. J Cell Biol. 1968;37:63-79.
18. Kaag S, Lorentz A. Effects of Dietary Components on Mast Cells: Possible Use as Nutraceuticals for Allergies? Cells. 2023;12.
19. Harman D. Aging: a theory based on free radical and radiation chemistry. J Gerontol. 1956;11:298-300.
20. Harrington JS, Ryter SW, Plataki M, Price DR, Choi AMK. Mitochondria in health, disease, and aging. Physiol Rev. 2023;103:2349-422.
21. Prattichizzo F, Bonafè M, Olivieri F, Franceschi C. Senescence associated macrophages and "macroph-aging": are they pieces of the same puzzle? Aging (Albany NY). 2016;8:3159-60.
22. Rinnerthaler M, Bischof J, Streubel MK, Trost A, Richter K. Oxidative stress in aging human skin. Biomolecules. 2015;5:545-89.
23. Gill V, Kumar V, Singh K, Kumar A, Kim JJ. Advanced Glycation End Products (AGEs) May Be a Striking Link Between Modern Diet and Health. Biomolecules. 2019;9.
24. Arck PC, Overall R, Spatz K, Liezman C, Handjiski B, Klapp BF, et al. Towards a "free radical theory of graying": melanocyte apoptosis in the aging human hair follicle is an indicator of oxidative stress induced tissue damage. Faseb j. 2006;20:1567-9.
25. Bahta AW, Farjo N, Farjo B, Philpott MP. Premature senescence of balding dermal papilla cells in vitro is associated with p16(INK4a) expression. J Invest Dermatol. 2008;128:1088-94.
26. Tobin DJ. Aging of the hair follicle pigmentation system. Int J Trichology. 2009;1:83-93.
27. Georgescu SR, Mitran CI, Mitran MI, Matei C, Popa GL, Erel O, et al. Thiol-Disulfide Homeostasis in Skin Diseases. J Clin Med. 2022;11.
28. Ji H, Li XK. Oxidative Stress in Atopic Dermatitis. Oxid Med Cell Longev. 2016;2016:2721469.
29. Chiba T, Tatematsu S, Nakao M, Furue M. Urinary biopyrrin: a potential inflammatory marker of atopic dermatitis. Ann Allergy Asthma Immunol. 2014;112:182-3.
30. Sivaranjani N, Rao SV, Rajeev G. Role of reactive oxygen species and antioxidants in atopic dermatitis. J Clin Diagn Res. 2013;7:2683-5.
31. Chen PY, Chen CW, Su YJ, Chang WH, Kao WF, Yang CC, et al. Associations between Levels of Urinary Oxidative Stress of 8-OHdG and Risk of Atopic Diseases in Children. Int J Environ Res Public Health. 2020;17.
32. Peroni DG, Bodini A, Corradi M, Coghi A, Boner AL, Piacentini GL. Markers of oxidative stress are increased in exhaled breath condensates of children with atopic dermatitis. Br J Dermatol. 2012;166:839-43.
33. Leman G, Pavel P, Hermann M, Crumrine D, Elias PM, Minzaghi D, et al. Mitochondrial Activity Is Upregulated in Nonlesional Atopic Dermatitis and Amenable to Therapeutic Intervention. J Invest Dermatol. 2022;142:2623-34.e12.
34. Seong MK, Shin M. Low-Density Lipoprotein Cholesterol Is Associated with Atopic Dermatitis in Korean Adolescents. Int Arch Allergy Immunol. 2023;184:1230-6.
35. Minzaghi D, Pavel P, Kremslehner C, Gruber F, Oberreiter S, Hagenbuchner J, et al. Excessive Production of Hydrogen Peroxide in Mitochondria Contributes to Atopic Dermatitis. J Invest Dermatol. 2023;143:1906-18.e8.

36. Focken J, Scheurer J, Jäger A, Schürch CM, Kämereit S, Riel S, et al. Neutrophil extracellular traps enhance S. aureus skin colonization by oxidative stress induction and downregulation of epidermal barrier genes. Cell Rep. 2023;42:113148.
37. Koch M, Kockmann T, Rodriguez E, Wehkamp U, Hiebert P, Ben-Yehuda Greenwald M, et al. Quantitative Proteomics Identifies Reduced NRF2 Activity and Mitochondrial Dysfunction in Atopic Dermatitis. J Invest Dermatol. 2023;143:220-31.e7.
38. Di Salvo E, Gangemi S, Genovese C, Cicero N, Casciaro M. Polyphenols from Mediterranean Plants: Biological Activities for Skin Photoprotection in Atopic Dermatitis, Psoriasis, and Chronic Urticaria. Plants (Basel). 2023;12.
39. Zawawi NA, Ahmad H, Madatheri R, Fadilah NIM, Maarof M, Fauzi MB. Flavonoids as Natural Anti-Inflammatory Agents in the Atopic Dermatitis Treatment. Pharmaceutics. 2025;17.
40. Kim JE, Yoo SR, Jeong MG, Ko JY, Ro YS. Hair zinc levels and the efficacy of oral zinc supplementation in patients with atopic dermatitis. Acta Derm Venereol. 2014;94:558-62.
41. Moon PD, Jeong HJ, Kim HM. Down-regulation of thymic stromal lymphopoietin by curcumin. Pharmacol Rep. 2013;65:525-31.
42. Sharma S, Naura AS. Potential of phytochemicals as immune-regulatory compounds in atopic diseases: A review. Biochem Pharmacol. 2020;173:113790.
43. Comberiati P, Pecoraro L, Pigozzi R, Peroni D, Piacentini G. Pearls and pitfalls of bathing in atopic dermatitis. Allergy Asthma Proc. 2019;40:204-6.
44. Su L, Wang F, Wang Y, Qin C, Yang X, Ye J. Circulating biomarkers of oxidative stress in people with acne vulgaris: a systematic review and meta-analysis. Arch Dermatol Res. 2024;316:105.
45. Bungau AF, Radu AF, Bungau SG, Vesa CM, Tit DM, Endres LM. Oxidative stress and metabolic syndrome in acne vulgaris: Pathogenetic connections and potential role of dietary supplements and phytochemicals. Biomed Pharmacother. 2023;164:115003.
46. Webster GF. Inflammation in acne vulgaris. J Am Acad Dermatol. 1995;33:247-53.
47. Bowe WP, Patel N, Logan AC. Acne vulgaris: the role of oxidative stress and the potential therapeutic value of local and systemic antioxidants. J Drugs Dermatol. 2012;11:742-6.
48. Erturan İ, Naziroğlu M, Akkaya VB. Isotretinoin treatment induces oxidative toxicity in blood of patients with acne vulgaris: a clinical pilot study. Cell Biochem Funct. 2012;30:552-7.
49. Zhang Y, Li Z, Ma Y, Mu Z. Association of total oxidant status, total antioxidant status, and malondialdehyde and catalase levels with psoriasis: a systematic review and meta-analysis. Clin Rheumatol. 2019;38:2659-71.
50. [Mizuguchi S, Gotoh K, Nakashima Y, Setoyama D, Takata Y, Ohga S, et al. Mitochondrial Reactive Oxygen Species Are Essential for the Development of Psoriatic Inflammation. Front Immunol. 2021;12:714897.
51. Therianou A, Vasiadi M, Delivanis DA, Petrakopoulou T, Katsarou-Katsari A, Antoniou C, et al. Mitochondrial dysfunction in affected skin and increased mitochondrial DNA in serum from patients with psoriasis. Exp Dermatol. 2019;28:72-5.
52. Beranek M, Borsky P, Fiala Z, Andrys C, Hamakova K, Chmelarova M, et al. Telomere length, oxidative and epigenetic changes in blood DNA of patients with exacerbated psoriasis vulgaris. An Bras Dermatol. 2023;98:68-74.
53. Wu K, Higashi N, Hansen ER, Lund M, Bang K, Thestrup-Pedersen K. Telomerase activity is increased and telomere length shortened in T cells from blood of patients with atopic dermatitis and psoriasis. J Immunol. 2000;165:4742-7.
54. Heng MC, Song MK, Harker J, Heng MK. Drug-induced suppression of phosphorylase kinase activity correlates with resolution of psoriasis as assessed by clinical, histological and immunohistochemical parameters. Br J Dermatol. 2000;143:937-49.
55. Bilia AR, Bergonzi MC, Isacchi B, Antiga E, Caproni M. Curcumin nanoparticles potentiate therapeutic effectiveness of acitrein in moderate-to-severe psoriasis patients and control serum cholesterol levels. J Pharm Pharmacol. 2018;70:919-28.
56. Antiga E, Bonciolini V, Volpi W, Del Bianco E, Caproni M. Oral Curcumin (Meriva) Is Effective as an Adjuvant Treatment and Is Able to Reduce IL-22 Serum Levels in Patients with Psoriasis Vulgaris. Biomed Res Int. 2015;2015:283634.
57. Galiniak S, Mołoń M, Biesiadecki M, Bożek A, Rachel M. The Role of Oxidative Stress in Atopic Dermatitis and Chronic Urticaria. Antioxidants (Basel). 2022;11.
58. Nettis E, Distaso M, Saitta S, Casciaro M, Cristani M, Saija A, et al. Involvement of new oxidative stress markers in chronic spontaneous urticaria. Postepy Dermatol Alergol. 2017;34:448-52.
59. Dilek F, Ozceker D, Ozkaya E, Guler N, Tamay Z, Kesgin S, et al. Oxidative Stress in Children with Chronic Spontaneous Urticaria. Oxid Med Cell Longev. 2016;2016:3831071.

60. Rajappa M, Chandrashekar L, Sundar I, Munisamy M, Ananthanarayanan PH, Thappa DM, et al. Platelet oxidative stress and systemic inflammation in chronic spontaneous urticaria. Clin Chem Lab Med. 2013;51:1789-94.
61. Arauna D, Navarrete S, Albala C, Wehinger S, Pizarro-Mena R, Palomo I, et al. Understanding the Role of Oxidative Stress in Platelet Alterations and Thrombosis Risk among Frail Older Adults. Biomedicines. 2024;12.
62. Metz M, Torene R, Kaiser S, Beste MT, Staubach P, Bauer A, et al. Omalizumab normalizes the gene expression signature of lesional skin in patients with chronic spontaneous urticaria: A randomized, double-blind, placebo-controlled study. Allergy. 2019;74:141-51.
63. Maurer M, Weller K, Bindslev-Jensen C, Giménez-Arnau A, Bousquet PJ, Bousquet J, et al. Unmet clinical needs in chronic spontaneous urticaria. A GA²LEN task force report. Allergy. 2011;66:317-30.
64. Dell'Anna ML, Ottaviani M, Kovacs D, Mirabilii S, Brown DA, Cota C, et al. Energetic mitochondrial failing in vitiligo and possible rescue by cardiolipin. Sci Rep. 2017;7:13663.
65. Kang P, Zhang W, Chen X, Yi X, Song P, Chang Y, et al. TRPM2 mediates mitochondria-dependent apoptosis of melanocytes under oxidative stress. Free Radic Biol Med. 2018;126:259-68.
66. Lin Y, Ding Y, Wu Y, Yang Y, Liu Z, Xiang L, et al. The underestimated role of mitochondria in vitiligo: From oxidative stress to inflammation and cell death. Exp Dermatol. 2024;33:e14856.
67. Speeckaert R, Dugardin J, Lambert J, Lapeere H, Verhaeghe E, Speeckaert MM, et al. Critical appraisal of the oxidative stress pathway in vitiligo: a systematic review and meta-analysis. J Eur Acad Dermatol Venereol. 2018;32:1089-98.
68. Romo-Tena J, Kaplan MJ. Immunometabolism in the pathogenesis of systemic lupus erythematosus: an update. Curr Opin Rheumatol. 2020;32:562-71.
69. Zhao L, Hu X, Xiao F, Zhang X, Wang M. Mitochondrial impairment and repair in the pathogenesis of systemic lupus erythematosus. Front Immunol. 2022;13:929520.
70. Liu L, de Leeuw K, van Goor H, Westra J. The Role of Antioxidant Transcription Factor Nrf2 and Its Activating Compounds in Systemic Lupus Erythematosus. Antioxidants (Basel). 2024;13.
71. Kamiński K, Kazimierczak U, Kolenda T. Oxidative stress in melanogenesis and melanoma development. Contemp Oncol (Pozn). 2022;26:1-7.
72. Menezo YJ, Silvestris E, Dale B, Elder K. Oxidative stress and alterations in DNA methylation: two sides of the same coin in reproduction. Reprod Biomed Online. 2016;33:668-83.
73. Denat L, Kadekaro AL, Marrot L, Leachman SA, Abdel-Malek ZA. Melanocytes as instigators and victims of oxidative stress. J Invest Dermatol. 2014;134:1512-8.
74. Bisevac JP, Djukic M, Stanojevic I, Stevanovic I, Mijuskovic Z, Djuric A, et al. Association Between Oxidative Stress and Melanoma Progression. J Med Biochem. 2018;37:12-20.
75. Feng Q, Xu X, Zhang S. Nrf2 protein in melanoma progression, as a new means of treatment. Pigment Cell Melanoma Res. 2024;37:247-58.
76. Emanuelli M, Sartini D, Molinelli E, Campagna R, Pozzi V, Salvolini E, et al. The Double-Edged Sword of Oxidative Stress in Skin Damage and Melanoma: From Physiopathology to Therapeutical Approaches. Antioxidants (Basel). 2022;11.
77. Fernando P, Zhen AX, Piao MJ, Herath H, Kang KA, Yoon SP, et al. Naringenin Induces Cellular Apoptosis in Melanoma Cells via Intracellular ROS Generation. Anticancer Res. 2024;44:1079-86.
78. Cano Sanchez M, Lancel S, Boulanger E, Neviere R. Targeting Oxidative Stress and Mitochondrial Dysfunction in the Treatment of Impaired Wound Healing: A Systematic Review. Antioxidants (Basel). 2018;7.
79. Deng L, Du C, Song P, Chen T, Rui S, Armstrong DG, et al. The Role of Oxidative Stress and Antioxidants in Diabetic Wound Healing. Oxid Med Cell Longev. 2021;2021:8852759.
80. Marton LT, Pescinini ESLM, Camargo MEC, Barbalho SM, Haber J, Sinatora RV, et al. The Effects of Curcumin on Diabetes Mellitus: A Systematic Review. Front Endocrinol (Lausanne). 2021;12:669448.
81. Changal KH, Khan MS, Bashir R, Sheikh MA. Curcumin Preparations Can Improve Flow-Mediated Dilation and Endothelial Function: A Meta-Analysis. Complement Med Res. 2020;27:272-81.
82. Meyskens FL, Jr., Liu-Smith F. Redox-Redux and NADPH Oxidase (NOX): Even More Complicated than We Thought it Might Be. J Invest Dermatol. 2017;137:1208-10.
83. Beavers WN, Skaar EP. Neutrophil-generated oxidative stress and protein damage in Staphylococcus aureus. Pathog Dis. 2016;74.
84. Gambino M, Cappitelli F. Mini-review: Biofilm responses to oxidative stress. Biofouling. 2016;32:167-78.
85. Sebastiano M, Chastel O, de Thoisy B, Eens M, Costantini D. Oxidative stress favours herpes virus

infection in vertebrates: a meta-analysis. Curr Zool. 2016;62:325-32.
86. Zhang L, Wang J, Wang Z, Li Y, Wang H, Liu H. Upregulation of nuclear factor E2-related factor 2 (Nrf2) represses the replication of herpes simplex virus type 1. Virol J. 2022;19:23.
87. Majeed N, Ismail F. In vitro characteristics of fungal biofilm formation and the influence of physiological stress on biofilm growth. Pak J Pharm Sci. 2023;36:103-9.
88. Brígido HPC, Dos Santos LGA, de Barros RC, Correa-Barbosa J, Santos P, Paz RFL, et al. The Role of Oxidative Stress in the Pathogenesis and Treatment of Leishmaniasis: Impact on Drug Toxicity and Therapeutic Potential of Natural Products. Toxics. 2025;13.
89. Zeldin J, Ratley G, Shobnam N, Myles IA. The clinical, mechanistic, and social impacts of air pollution on atopic dermatitis. J Allergy Clin Immunol. 2024;154:861-73.
90. O'Rourke SA, Shanley LC, Dunne A. The Nrf2-HO-1 system and inflammaging. Front Immunol. 2024;15:1457010.
91. Esquirol Y, Ferrières J, Marquie J-C, Huo-Yung-Kai S, Bérard E, Bongard V, et al. Wrinkles and risk of death (total and cardiovascular mortality) in a middle-aged working population. 2018;10:125-6.
92. Gude D. Hair loss: a harbinger of the morbidities to come! Int J Trichology. 2012;4:287-8.
93. Silverwood RJ, Forbes HJ, Abuabara K, Ascott A, Schmidt M, Schmidt SAJ, et al. Severe and predominantly active atopic eczema in adulthood and long term risk of cardiovascular disease: population based cohort study. Bmj. 2018;361:k1786.
94. Yaghmaie P, Koudelka CW, Simpson EL. Mental health comorbidity in patients with atopic dermatitis. J Allergy Clin Immunol. 2013;131:428-33.
95. Zhou W, Cai J, Li Z, Lin Y. Association of atopic dermatitis with autoimmune diseases: A bidirectional and multivariable two-sample mendelian randomization study. Front Immunol. 2023;14:1132719.
96. Matthewman J, Schultze A, Strongman H, Bhaskaran K, Roberts A, Denaxas S, et al. Cohort studies on 71 outcomes among people with atopic eczema in UK primary care data. Nat Commun. 2024;15:9573.
97. Chen TL, Tsai HR, Chang WC, Lu JW, Chen YJ, Lee YC, et al. Risk of age-related macular degeneration in late-onset atopic dermatitis: A multi-database cohort analysis. Retina. 2025.
98. Liu JH, Chen Y, Zhen Z, Yeung CK, Chan J, Chan HH, et al. Relation between endothelial progenitor cells and arterial stiffness in patients with psoriasis. J Dermatol. 2016;43:888-93.
99. WHO. Global report on psoriasis. 2006.
100. Yue L, Pang B, Li G, Zhang C, Li Q, Li K, et al. Endothelial Piezo1 Mediates Barrier Dysfunction and NLRP3 Inflammasomes Activation in Psoriasis. J Invest Dermatol. 2025;145:2484-94.e5.
101. Wen S, Elias PM, Wakefield JS, Mauro TM, Man MQ. The link between cutaneous inflammation and cognitive impairment. J Eur Acad Dermatol Venereol. 2022;36:1705-12.
102. Tsai SY, Chen LC, Harris JE, Garza-Mayers AC. Auditory and Ocular Manifestations in Pediatric Vitiligo. JAMA Dermatol. 2025;161:879-81.
103. Frączek A, Owczarczyk-Saczonek A, Ludwig RJ, Hernandez G, Ständer S, Thaci D, et al. Vitiligo is associated with an increased risk of cardiovascular diseases: a large-scale, propensity-matched, US-based retrospective study. EBioMedicine. 2024;109:105423.
104. Xia J, Melian C, Guo W, Usmani H, Clark R, Lozeau D. Vitiligo and Metabolic Syndrome: Systematic Review and Meta-Analysis. JMIR Dermatol. 2022;5:e34772.
105. Murdaca G, Paladin F, Borro M, Ricciardi L, Gangemi S. Prevalence of Autoimmune and Autoinflammatory Diseases in Chronic Urticaria: Pathogenetic, Diagnostic and Therapeutic Implications. Biomedicines. 2023;11.
106. Mohammed GF, Al-Dhubaibi MS, Bahaj SS, AbdElneam AI, Al-Dhubaibi AM, Atef LM. Acne vulgaris: a warning sign for diagnosing metabolic syndrome. Arch Dermatol Res. Germany2024. p. 5.
107. Pecoraro L, Zoller T, Atkinson RL, Nisi F, Antoniazzi F, Cavarzere P, et al. Supportive treatment of vascular dysfunction in pediatric subjects with obesity: the OBELIX study. Nutr Diabetes. 2022;12:2.
108. Münzel T, Gori T, Bruno RM, Taddei S. Is oxidative stress a therapeutic target in cardiovascular disease? Eur Heart J. 2010;31:2741-8.
109. Schmidt HH, Stocker R, Vollbracht C, Paulsen G, Riley D, Daiber A, et al. Antioxidants in Translational Medicine. Antioxid Redox Signal. 2015;23:1130-43.
110. Khaw KT, Bingham S, Welch A, Luben R, Wareham N, Oakes S, et al. Relation between plasma ascorbic acid and mortality in men and women in EPIC-Norfolk prospective study: a prospective population study. European Prospective Investigation into Cancer and Nutrition. Lancet. 2001;357:657-63.
111. Buonsenso D, Di Gennaro L, De Rose C, Morello R, D'Ilario F, Zampino G, et al. Long-term outcomes of pediatric infections: from traditional infectious diseases to long Covid. Future Microbiol. 2022;17:551-71.

112. Elmadfa I, Meyer A, Nowak V, Hasenegger V, Putz P, Verstraeten R, et al. European Nutrition and Health Report 2009. Forum Nutr. 2009;62:1-405.
113. Gombart AF, Pierre A, Maggini S. A Review of Micronutrients and the Immune System-Working in Harmony to Reduce the Risk of Infection. Nutrients. 2020;12.
114. Maggini S, Óvári V, Ferreres Giménez I, Pueyo Alamán MG. Benefits of micronutrient supplementation on nutritional status, energy metabolism, and subjective wellbeing. Nutr Hosp. 2021;38:3-8.
115. Perkins AV, Vanderlelie JJ. Multiple micronutrient supplementation and birth outcomes: The potential importance of selenium. Placenta. 2016;48 Suppl 1:S61-s5.
116. Priliani L, Prado EL, Restuadi R, Waturangi DE, Shankar AH, Malik SG. Maternal Multiple Micronutrient Supplementation Stabilizes Mitochondrial DNA Copy Number in Pregnant Women in Lombok, Indonesia. J Nutr. 2019;149:1309-16.
117. Kohzadi M, Kubow S, Koski KG. Fetal Growth Is Associated with Amniotic Fluid Antioxidant Capacity, Oxidative Stress, Minerals and Prenatal Supplementation: A Retrospective Study. Antioxidants (Basel). 2025;14.
118. Dragan S, Buleu F, Christodorescu R, Cobzariu F, Iurciuc S, Velimirovici D, et al. Benefits of multiple micronutrient supplementation in heart failure: A comprehensive review. Crit Rev Food Sci Nutr. 2019;59:965-81.
119. Valla FV, Bost M, Roche S, Pitance M, Cuerq C, Ridout J, et al. Multiple Micronutrient Plasma Level Changes Are Related to Oxidative Stress Intensity in Critically Ill Children. Pediatr Crit Care Med. 2018;19:e455-e63.
120. Alarcón-Moreno JC, Flores-Muñoz M, Blázquez-Morales MSL, García-Rivera ME, Rodríguez-Alba JC, Castro-López CR, et al. "The effects of non-surgical periodontal treatment plus zinc and magnesium supplementation on oxidative stress and antioxidants enzymes in type 2 diabetes patients: a quasi-experimental study". BMC Oral Health. 2024;24:892.
121. Alhussien MN, Tiwari S, Panda BSK, Pandey Y, Lathwal SS, Dang AK. Supplementation of antioxidant micronutrients reduces stress and improves immune function/response in periparturient dairy cows and their calves. J Trace Elem Med Biol. 2021;65:126718.
122. Fink B, Hunter JM, Pietrzkowski Z, Fink R, Brunssen C, Morawietz H, et al. A Plant-Based Dietary Supplement Exhibits Significant Effects on Markers of Oxidative Stress, Inflammation, and Immune Response in Subjects Recovering from Respiratory Viral Infection: A Randomized, Double-Blind Clinical Study Using Vitamin C as a Positive Control. Int J Mol Sci. 2025;26.
123. Wu D, Lewis ED, Pae M, Meydani SN. Nutritional Modulation of Immune Function: Analysis of Evidence, Mechanisms, and Clinical Relevance. Front Immunol. 2018;9:3160.
124. Schmoranzer F, Fuchs N, Markolin G, Carlin E, Sakr L, Sommeregger U. Influence of a complex micronutrient supplement on the immune status of elderly individuals. Int J Vitam Nutr Res. 2009;79:308-18.
125. Girodon F, Galan P, Monget AL, Boutron-Ruault MC, Brunet-Lecomte P, Preziosi P, et al. Impact of trace elements and vitamin supplementation on immunity and infections in institutionalized elderly patients: a randomized controlled trial. MIN. VIT. AOX. geriatric network. Arch Intern Med. 1999;159:748-54.
126. Stephen AI, Avenell A. A systematic review of multivitamin and multimineral supplementation for infection. J Hum Nutr Diet. 2006;19:179-90.
127. Xian D, Guo M, Xu J, Yang Y, Zhao Y, Zhong J. Current evidence to support the therapeutic potential of flavonoids in oxidative stress-related dermatoses. Redox Rep. 2021;26:134-46.
128. Armstrong E, Boonekamp J. Does oxidative stress shorten telomeres in vivo? A meta-analysis. Ageing Res Rev. 2023;85:101854.
129. Ames BN. Prolonging healthy aging: Longevity vitamins and proteins. Proc Natl Acad Sci U S A. 2018;115:10836-44.
130. Zia A, Farkhondeh T, Pourbagher-Shahri AM, Samarghandian S. The role of curcumin in aging and senescence: Molecular mechanisms. Biomed Pharmacother. 2021;134:111119.
131. Miller ER, 3rd, Pastor-Barriuso R, Dalal D, Riemersma RA, Appel LJ, Guallar E. Meta-analysis: high-dosage vitamin E supplementation may increase all-cause mortality. Ann Intern Med. 2005;142:37-46.
132. Halliwell B. The antioxidant paradox. Lancet. 2000;355:1179-80.
133. Forman HJ, Davies KJ, Ursini F. How do nutritional antioxidants really work: nucleophilic tone and para-hormesis versus free radical scavenging in vivo. Free Radic Biol Med. 2014;66:24-35.
134. Halliwell B, Gutteridge JM. Free radicals in biology and medicine: Oxford university press; 2015.
135. Shen X, Wang C, Zhou X, Zhou W, Hornburg D, Wu S, et al. Nonlinear dynamics of multi-omics profiles during human aging. Nat Aging. 2024.
136. Smith JR, Pike JR, Gottesman RF, Knopman DS,

Lutsey PL, Palta P, et al. Contribution of Modifiable Midlife and Late-Life Vascular Risk Factors to Incident Dementia. JAMA Neurol. 2025;82:644-54.

INTERNATIONAL JOURNAL
of PEDIATRIC DERMATOLOGY

Special Issue, 2025
ISSN 3035-1006 online

Comprehensive Review

Gynecological Dermatology in Pediatric Age: a Comprehensive Overview

Maria Borodina[1], Julia Sigova[2,4], Yan Valle[3], Torello Lotti[4] and Fabio Arcangeli[4]

[1]Russian Children's Clinical Hospital, Pirogov Russian National Research Medical University, Moscow, Russia; [2]Department of Neonatology, Faculty of Continued Medical Education, Pirogov Russian National Research Medical University, Moscow, Russia; [3] Vitiligo Research Foundation, New York, USA; [4]G. Marconi University, Rome, Italy

KEYWORDS

Dermatitis
Gynecologic
Lichen sclerosus
Pinworms
Psoriasis
Vitiligo
Vulvar disease
Vulvovaginitis

CORRESPONDING AUTHOR

Prof. Fabio Arcangeli,
Guglielmo Marconi
Univeristy,
Rome, Italy
e-mail: fabio.arcangeli4@gmail.com

ABSTRACT

Pediatric gynecologic dermatology encompasses non-sexually transmitted vulvar and perineal dermatoses in children and adolescents, requiring age-specific examination, diagnosis, and management approaches. This comprehensive review synthesizes epidemiology, clinical features, and evidence-based management of common conditions — nonspecific/irritant vulvovaginitis, vulvar lichen sclerosus, contact dermatitis, inflammatory and pigmentary dermatoses, infections, and anatomical variants — alongside critical but rare systemic diseases including hidradenitis suppurativa, Crohn's disease, and Behçet disease. We emphasize diagnostic challenges, safeguarding considerations, psychosocial impact, and the importance of multidisciplinary care models. Key knowledge gaps include standardizing maintenance protocols for chronic conditions, reducing diagnostic delays, and improving recognition across diverse skin tones.

Copyright 2025 © by World Health Academy Publishing House
This publication and/or article is for individual use only and may not be further reproduced without written permission from the copyright holder.
Unauthorized reproduction may result in financial and other penalties
DISCLOSURE: ALL AUTHORS REPORT NO CONFLICTS OF INTEREST RELEVANT TO THIS ARTICLE.

Introduction

Gynecologic dermatology in the pediatric population represents a specialized intersection of dermatology and gynecology, focusing on non-sexually transmitted vulvar and perineal skin conditions affecting children and adolescents (0-18 years). The clinical presentation, differential diagnosis, and management of these conditions differ substantially from adult counterparts due to unique anatomical, physiological, hormonal, and psychosocial factors (1-3).

Epidemiological data from large pediatric series demonstrate that nonspecific/irritant vulvovaginitis accounts for the majority of presentations, followed by inflammatory dermatoses and vulvar lichen sclerosus (1, 2). However, the spectrum includes rare but clinically significant systemic conditions that may present with genital manifestations as the initial or predominant feature (3, 4). Early recognition, accurate diagnosis, and appropriate management are essential to prevent symptom chronicity, psychological distress, long-term complications such as scarring, and optimization of quality of life (5, 6).

Pediatric vulvar anatomy and physiology (why children differ)

The hypoestrogenic state characteristic of prepubertal girls results in distinct anatomical and physiological features that predispose to specific dermatological conditions. The vulvar epithelium is thinner and less keratinized, with reduced protective mucus production and fewer protective lactobacilli, resulting in a relatively alkaline pH environment (7, 8). These factors, combined with anatomical features such as the shorter anogenital distance and increased susceptibility to occlusion, friction, and chemical irritants, create a unique vulnerability profile (9).

Clinical assessment must account for variations in presentation across different skin tones, where traditional markers such as erythema may be less apparent, and alternative signs including textural changes, hypopigmentation, or hyperpigmentation may be more diagnostically significant (10).

Clinical Spectrum: common and rare dermatoses

Nonspecific/irritant vulvovaginitis

Typical in school-aged children, often seasonal (heat/sweat) and hygiene-linked. Symptoms: itch, burning, dysuria, transient discharge, behavioral changes (withholding urine/stool). Physical examination reveals erythema, excoriation, and possible maceration without systemic signs.

Management prioritizes irritant elimination and barrier repair: lukewarm water only; soap substitute for folds; pat dry; petrolatum-based emollient after bathing and after voiding/defecation for 1–2 weeks; breathable cotton underwear; avoid baby wipes, bubble baths, fragrances, and tight synthetics. Reserve antibiotics for compatible symptoms with pure or predominant pathogen growth on culture; consider a pinworm tape test in nocturnal pruritus (1, 11).

Vulvar lichen sclerosus (VLS)

Vulvar lichen sclerosus (VLS) represents a critical diagnosis due to its potential for progressive scarring, functional impairment, and long-term complications. The condition demonstrates a bimodal age distribution, with the prepubertal peak occurring around 5-7 years of age (12, 13).

Clinical: The pathognomonic “figure-8” distribution involves the vulva and perianal region (Fig.1), presenting with porcelain-white plaques, textural changes, purpura, fissures, and erosions. Associated symptoms include intense pruritus, pain, dysuria, and constipation.

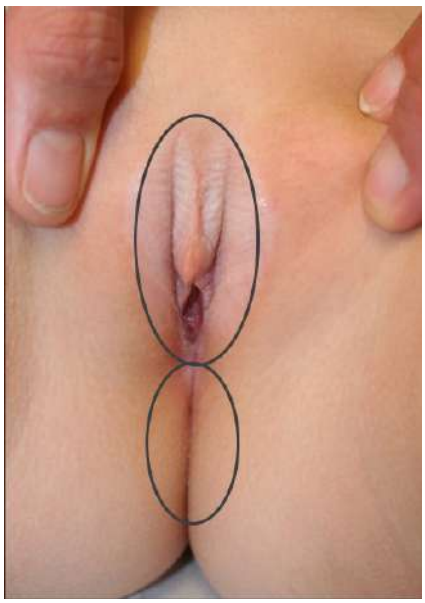

Fig. 1. *Atrophic skin with a lardaceous appearance in the vulvar and perianal regions, with the typical "figure-8" configuration.*

Management: ultrapotent topical corticosteroid (e.g., clobetasol 0.05% ointment) once daily for 4-8 weeks for induction, then individualized step-down (alternate day 2-3 times/week) with proactive maintenance in relapsing disease. Studies demonstrate 65-100% symptom resolution and 20-70% complete remission with clobetasol treatment, though 45% require maintenance therapy. Generous emollients; constipation plan; education on gentle skin care. Routine biopsy is unnecessary when presentation is classic and response is satisfactory; reserve for atypical or refractory cases. Long-term follow-up is recommended; persistence into adolescence/adulthood is common in up to 75% of cases, though remission is variable.

Alternative treatments: Topical calcineurin inhibitors (tacrolimus 0.03% ointment) show efficacy in pediatric VLS. Studies demonstrate clinical improvement in all treated children, with reduced recurrence rates when maintenance therapy (twice weekly for six months) is employed compared to shorter treatment courses. These agents are particularly useful as steroid-sparing maintenance therapy (7–12).

VLS may persist into adulthood, necessitating long-term surveillance for disease activity, treatment response, and rare malignant transformation (5, 17).

Inflammatory dermatoses

Contact dermatitis

Both irritant and allergic contact dermatitis commonly affect the vulvar region, often overlapping with non-specific vulvovaginitis. Common triggers include fragranced products (like wipes, fragranced soaps, bubble baths), wet clothing, detergents, and topical medications. Management involves trigger identification and elimination, short-course mild-to-moderate potency topical corticosteroids, and comprehensive barrier care protocols., laundry detergents, tight/occlusive clothing, wet swimsuits, chlorine without rinse-off, urine/stool.

Psoriasis

Psoriasis may present with well-demarcated erythema (often minimal scale in the vulva) (Fig. 2), fissures, and itch; look for extra-genital clues (scalp, flexures, nails). Well-demarcated erythematous plaques may be accompanied by extragenital manifestations including scalp, nail, and joint involvement (18).

Fig. 2. *Psoriasis of the vulvar and perigenital regions. Well-demarcated erythema with minimal scale.*

Treatment considerations include mild coal tar preparations, which have shown effectiveness in clearing genital lesions in pediatric patients. Topical corticosteroids ranging from low to high potency have been successfully used, with moderate-to-high-potency steroids showing effectiveness both as monotherapy and in combination treatments. Low-potency topical corticosteroids can achieve clearance in as little as 2 weeks, while potent steroids like clobetasol 0.05% ointment may provide complete resolution within 4 weeks for severe cases.

Pediatric patients with psoriasis warrant screening for associated comorbidities including metabolic syndrome, arthritis, and inflammatory bowel disease (19).

Atopic dermatitis

Atopic dermatitis affecting the vulvar area requires gentle management with emollients and mild topical corticosteroids. Mid- to high-potency topical steroids such as triamcinolone and clobetasol are recommended for inflammatory control, though careful monitoring for skin atrophy is essential in this sensitive area. Topical calcineurin inhibitors (pimecrolimus 1% cream or tacrolimus 0.1% ointment) serve as effective steroid-sparing alternatives for maintenance therapy (18).

Pigmentary Disorders

Vitiligo presents as asymptomatic depigmentation without texture change, purpura, or fissuring and should be distinguished from VLS (Fig. 3). Childhood vitiligo represents approximately 25% of all vitiligo cases, with mean age of onset between 4-8 years in various studies (20). Congenital vitiligo, while extremely rare, does occur and has been reported in neonates present from birth. The exact prevalence of congenital vitiligo is unknown, but case reports suggest it represents a very small fraction of childhood vitiligo cases, with one Chinese study reporting only 8 children with lesions present at birth out of 541 childhood vitiligo cases (1.5%) (21). Segmental vitiligo (SV) is more common in children (17-29%) compared to adults (5%) and may present very early, sometimes soon after birth. Treatment follows standard pediatric protocols with topical corticosteroids and calcineurin inhibitors, though many cases in the genital area may be managed with observation and reassurance alone. Pediatric vitiligo warrants screening for associated autoimmune and endocrine comorbidities including thyroid dysfunction, type 1 diabetes, and adrenal insufficiency (22).

Fig. 3. *Perigenital vitiligo. Depigmentation without texture change, purpura, or fissuring.*

Infectious and Infestation Conditions

Molluscum contagiosum presents as small, flesh-colored, dome-shaped papules with central umbilication. The condition has a global prevalence of 2-8% among children, with the highest incidence in children under 5 years of age. MCV-1 accounts for 98% of cases in children, while transmission occurs through direct skin-to-skin contact or contaminated objects such as towels and bath sponges (23). Swimming pool usage has been correlated with childhood infections. In the genital area, molluscum in younger children is typically non-sexual in transmission, though safeguarding assessment may be warranted in older children. The condition is generally self-limiting, resolving spontaneously over months to years, though treatment may be considered for cosmetic reasons or to prevent spread.

Pinworm Infestation (Enterobius vermicularis) is extremely common and frequently causes nocturnal perineal and vulvar pruritus. Global prevalence studies show significant variation, with rates of 3.6-22% in different pediatric populations. The highest prevalence occurs in children aged 3-6 years (up to 5% in some studies), with school-aged children being most commonly affected. In the United States, approximately 20% of children develop pinworm infection at some point. The classic symptom is nocturnal itching due to female worms migrating to lay eggs around the anus. Diagnosis is confirmed through the cellophane tape test performed in the morning before bathing. Treatment involves anthelmintics (mebendazole, pyrantel pamoate, or albendazole) with treatment of household contacts and emphasis on hygiene measures including handwashing, daily morning bathing, and daily underwear changes (24).

Group A Streptococcal Vulvovaginitis represents with acute onset of severe pain, erythema, and purulent discharge, often with systemic symptoms. This represents one of the few true bacterial infections of the vulva in prepubertal children and requires prompt recognition and antibiotic therapy based on culture and local antimicrobial guidelines (11).

Anogenital Warts (HPV Infection) caused by human papillomavirus (HPV) can occur in childhood and are often non-sexual in transmission, particularly in younger children. Modes of transmission include vertical transmission, autoinoculation, and heteroinoculation (e.g., from caregivers).

However, careful clinical assessment is essential, particularly in older children and adolescents, where sexual transmission becomes more likely. The presence of anogenital warts should prompt a safeguarding evaluation when indicated by the clinical history, examination findings, or behavioral context.

Management typically includes watchful waiting, topical treatments (e.g., imiquimod, podophyllotoxin), or surgical options depending on lesion burden, symptoms, and parental preference. In many cases, reassurance and conservative management are appropriate.

Anatomical Variants and Adhesions

Labial Adhesions affect up to 2% of prepubertal girls, with typical presentation at 2 years of age. The condition involves fusion of the labia minora due to inflammation in a low-estrogen environment, though some studies question whether hypoestrogenism is the primary cause (25).

Clinical presentation: Most cases are asymptomatic and discovered incidentally during routine examination. The fusion typically occurs near the clitoris and consists of thin fibrotic tissue ranging from partial to complete fusion occluding the vaginal orifice. When symptomatic, patients may present with post-void dribbling, dysuria, hematuria, local inflammation, difficulty voiding, or urinary retention. Urinary tract infections are associated with labial adhesions, with successful resolution of adhesions reducing UTI risk.

Management: Asymptomatic cases require only observation and reassurance, as up to 80% resolve spontaneously within one year. When treatment is indicated (primarily for UTIs or significant symptoms), topical estrogen cream is first-line therapy with success rates up to 90%. Alternative topical treatments include betamethasone, though studies show no statistically significant difference in efficacy compared to estrogen cream. Treatment duration is typically once or twice daily for up to 6 weeks, though some authors recommend up to 3 months. Potential side effects of estrogen cream include breast tenderness and local pigmentation changes.

Surgical management is reserved for cases where topical management fails after several weeks of therapy. Surgical lysis is performed under general anesthesia using gentle traction. Recurrence rates are significant (11-14%) regardless of treatment modality, and adhesions may continue reforming until puberty. Manual separation with proper hygiene maintenance is another treatment option in select cases.

Follow-up: Regular monitoring is important as recurrences are common. In resource-limited settings, some families prefer immediate surgical management due to financial and transportation constraints for repeated clinic visits, though conservative management remains the preferred approach when feasible.

Rare Papular and Nodular Lesions. Systematic studies of pediatric anogenital papular lesions identify several important entities including perianal pseudoverrucous papules and nodules (PPPN), representing 35% of anogenital papules in children >5 years, and infantile perineal pyramidal protrusion (IPPP), accounting for 7% of cases (26).

Systemic Diseases with Genital Manifestations

Hidradenitis suppurativa (HS) demonstrates increasing recognition in pediatric populations, with estimated prevalence of 0.7-1.2% in European and US populations. Pediatric-specific data reveal mean age of onset at 12.5 years, with 80% female predominance (27).

Clinical Characteristics: Early-onset HS frequently presents with genital/groin involvement and more severe disease patterns. Common presentations include painful nodules, abscesses, sinus tracts, and progressive scarring affecting inguinal folds (47%) and genital regions.

Associated Comorbidities: Pediatric HS demonstrates significant comorbidity burden including obesity (65%), acne vulgaris (29%), and metabolic syndrome components.

Management Approach: Treatment strategies include topical antimicrobials, systemic antibiotics, and biological therapies (adalimumab) for severe cases. Early multidisciplinary intervention is essential to prevent progressive scarring and functional impairment (28).

Crohn's Disease with Vulvar Involvement. Vulvar Crohn's disease (VCD) represents a rare but clinically significant manifestation affecting the pediatric population. Systematic review data identify vulvar involvement occurring in two forms: contiguous lesions (fistulas/fissures) and metastatic/noncontiguous cutaneous manifestations (29).

Clinical Presentation: Common manifestations include vulvar erythema, swelling, edema, and ulceration, with perianal involvement documented in 45% of cases. Critically, vulvar involvement may precede gastrointestinal symptoms in up to 33% of pediatric cases, representing the initial disease manifestation (29, 30).

Treatment Outcomes: Multimodal therapy including corticosteroids, metronidazole, azathioprine, and anti-TNF inhibitors demonstrates clinical remission in approximately 50% of cases. Anti-TNF therapy shows particularly favorable responses, with 92% of patients demonstrating clinical benefit.

Pediatric Behçet Disease accounts for up to 25% of all cases, with significant genital involvement representing a major diagnostic criterion (31). Juvenile-onset disease demonstrates distinct epidemiological and clinical characteristics compared to adult presentations. Genital Manifestations: Genital ulcers occur in 55-83% of pediatric cases, representing the second most com-

mon finding after oral ulceration. Pediatric genital lesions are typically painful, deep, and irregular, though scarring is less common than in adults (31, 32).

Management Considerations: Treatment approaches include colchicine, immunosuppressive agents (azathioprine, methotrexate), corticosteroids, and biological therapies (anti-TNF inhibitors) based on disease severity and organ involvement.

Diagnostic approach

History and examination

Elicit symptoms, duration, triggers (cleansers, clothing, swimming), bowel/bladder habits, scratching, sleep disturbance, prior therapies, comorbidities, and family history of dermatoses/autoimmunity (33). Include a sensitive, non-leading screen for trauma/abuse when indicated.

Child-friendly external examination only: frog-leg on caregiver's lap or knee-chest; gentle labial separation; chaperone; assent; careful documentation and Tanner staging. Avoid speculum and intravaginal swabs in prepubertal children. Photodocumentation requires explicit consent.

Tests and procedures (when to do them)

Swabs/cultures only when there is compatible infection (bloody discharge, systemic features, acute severe pain, failure of first-line care). Consider a tape test for suspected pinworms. Biopsy is rarely needed in children; reserve for atypical or unresponsive disease and perform by an experienced clinician. Ultrasound is for masses; radiology is not routine in dermatoses.

Red flags and referral thresholds

Ulceration, necrosis, unexplained purpura/ecchymoses, severe pain, dysuria with retention, fever/systemic illness, persistent/bloody discharge, mass, suspected foreign body, STI positivity, suspected abuse, examination not tolerated, diagnostic uncertainty after first-line care, or failure of appropriate therapy warrant urgent specialist review (34).

For practical guidance, the main presenting symptoms, differential diagnoses, and first-line management strategies are summarized in Table I.

Table I. *Symptom-led diagnostic cheat-sheet (prepubertal focus).*

Lead symptom/ sign	Top differentials	First checks/tests (only if indicated)	First-line management
Itch ± burning, no systemic illness	Irritant/contact dermatitis; nonspecific vulvovaginitis; psoriasis/AD; pinworms (nocturnal)	Pinworm tape test if nocturnal pruritus; swab only if purulent/bloody discharge	Barrier routine; remove irritants; short course mild–moderate topical steroid for flares
Pain with fissures, constipation; white plaques	Vulvar lichen sclerosus	Clinical diagnosis; biopsy only if atypical or refractory	Clobetasol 0.05% ointment induction → step-down/maintenance; emollients; constipation plan
Acute severe pain, erythema, purulent discharge, fever	Bacterial vulvovaginitis (e.g., GAS)	Introital/perineal swab/culture; consider UA if dysuria	Barrier routine; targeted antibiotics per culture/local guidance
Nocturnal perineal itch	Pinworms	Tape test; assess contacts	Anthelmintic (per local protocol); treat household; hygiene measures
Smooth papules/ umbilicated papules	Molluscum contagiosum	Clinical	Reassurance; avoid irritation/autoinoculation; consider lesion-directed therapy if bothersome

Lead symptom/ sign	Top differentials	First checks/tests (only if indicated)	First-line management
Depigmented macules/patches, asymptomatic	Vitiligo	Clinical; Wood's lamp if needed	Reassurance; topical therapy per standard pediatric protocols if desired; sun protection
Post-void dribbling, partial fusion	Labial adhesions	Clinical; exclude infection/trauma	Observation ± emollient; topical estrogen if symptomatic; rare gentle separation by experienced clinician

Management principles

Universal care measures ("barrier routine")

Lukewarm water only; soap substitute for folds; avoid wipes, fragrances, bubble baths; pat dry; petrolatum-based ointment after bathing and after voiding/defecation for 1–2 weeks; breathable cotton underwear; sleep without underwear if irritated; post-sport quick rinse; barrier pre-swim for frequent swimmers.

Pharmacologic interventions (see Table II)

Short, appropriate-potency topical corticosteroids for inflammatory flares; ultrapotent induction and tailored maintenance for VLS; topical calcineurin inhibitors as steroid-sparing maintenance in selected cases; targeted antibiotics only when clear bacterial etiology; anthelmintics for confirmed/suspected pinworms; topical estrogen for symptomatic labial adhesions (7–12).

Table II. *Practical treatment regimens and follow-up (summarized).*

Condition	First-line regimen	Maintenance/step-down	Follow-up & notes
Vulvar lichen sclerosus	Clobetasol 0.05% ointment thin layer once daily for 4–8 weeks (induction)	Taper to alternate-day for 2–4 weeks → 2–3×/week; consider proactive low-frequency steroid or calcineurin inhibitor (e.g., tacrolimus 0.03% ointment) in relapsing disease	Review at ~6–12 weeks, then 6–12-monthly; reinforce emollients, bowel care; biopsy only if atypical/ non-responsive
Nonspecific/irritant vulvovaginitis	Barrier routine; remove irritants	Emollient barrier daily for 1–2 weeks; repeat during flares	No routine tests; swab only if red flags or persistent discharge
Contact dermatitis (vulvar)	Mild–moderate potency topical corticosteroid for 5–7 days; barrier routine	Emollient barrier; avoid triggers; short steroid bursts for recurrences	Educate on ointment vehicles; review if frequent relapses to reassess triggers
Psoriasis/AD (vulvar)	Low-to-moderate potency topical corticosteroid short course; consider calcineurin inhibitor	Calcineurin inhibitor for maintenance in sensitive sites	Screen for extra-genital disease; gentle care to minimize stinging
Bacterial vulvovaginitis (e.g., GAS)	Targeted oral antibiotic per culture/local guideline	None	Reassess hygiene; consider pinworm assessment if relapsing
Pinworms	Anthelmintic (per local guidance), treat contacts	Hygiene, repeat dose per protocol	Address nocturnal scratching; nail care

Condition	First-line regimen	Maintenance/step-down	Follow-up & notes
Labial adhesions	Observe if asymptomatic; topical estrogen short course if symptomatic/obstructive	Emollient to reduce recurrence	Avoid forceful separation; specialist if dense/recurrent

Long-term management

Schedule review to confirm response, reinforce skin care, and adjust maintenance. VLS requires structured long-term surveillance to monitor for relapse and scarring; counsel families on excellent symptom control with adherence (36). Coordinate with pediatric gynecology when scarring, ulceration, diagnostic uncertainty, or comorbid pelvic pathology is present.

Psychological and social considerations

Symptoms affect sleep, school participation, and self-image; caregiver anxiety can amplify distress and care-seeking. Provide clear, jargon-light explanations; normalize common conditions; teach practical routines; and offer written instructions. Consider brief screening for anxiety/constipation/sleep disturbance and refer to psychology when persistent functional impairment is present (6, 37).

Multidisciplinary care

Combined pediatric dermatology–gynecology pathways or clinics improve diagnostic accuracy, reduce time-to-treatment, streamline procedures (when needed), and support longitudinal follow-up. Include pediatrics, urology, psychology/child protection, and surgery as needed. Suggested referral triggers are summarized above (1, 38).

Prevention and health promotion

Primary: avoid irritants, adopt barrier routines, bowel/voiding habits, breathable clothing.

Secondary: early recognition of VLS and other dermatoses; prompt treatment; structured follow-up for chronic disease; family education.

Future directions

Prospective pediatric VLS cohorts with standardized induction/maintenance and relapse definitions; trials comparing proactive weekend steroid vs calcineurin maintenance; image libraries across skin tones and ages; validated genital-specific pediatric QoL tools; implementation research on multidisciplinary clinics and caregiver education (39, 40).

Conclusion

Pediatric gynecologic dermatology demands developmentally sensitive examination, disciplined diagnostic thresholds, and practical, family-centered regimens. Early, accurate diagnosis is essential to prevent chronic symptoms, psychosocial distress, and long-term complications such as scarring, especially in conditions like vulvar lichen sclerosus—which requires timely recognition, ultrapotent steroid induction, and proactive maintenance with long-term review. Interdisciplinary care models and robust psychosocial support can improve outcomes and equity.

Clinicians must remain vigilant for rare presentations,

such as congenital vitiligo or genital psoriasis, as these may signal underlying autoimmune or metabolic disease and merit additional comorbidity screening. Psoriasis, especially with extensive or genital involvement, warrants ongoing monitoring for systemic associations such as obesity, metabolic syndrome, and arthritis.

Future work should prioritize standardizing steroid maintenance protocols, further reducing diagnostic delays, and improving recognition across all skin tones to address disparities in care. Research into pediatric-specific regimens, outcome tools, and image libraries—including for children with richly pigmented skin—will be vital for equitable practice. Comprehensive, anticipatory care—grounded in clear communication, targeted surveillance, and multidisciplinary collaboration—optimizes both physical and emotional health in children and adolescents with vulvar or genital dermatoses.

References

1. Menta N, Nussbaum D, Khilnani A, Dowlut-McElroy T, Habeshian KA. Insights from a joint pediatric dermatology-gynecology vulvar clinic: A retrospective study. Pediatr Dermatol. 2024 Jan-Feb;41(1):41-45. doi: 10.1111/pde.15489.
2. Gao H, Zhang Y, Pan Y, Zhao M, Qi Y, Zhou M, Chan SSC, Huang S, Song P, Tang K, Sun L, Yuan C. Patterns of pediatric and adolescent female genital inflammation in China: an eight-year retrospective study of 49,175 patients in China. Front Public Health. 2023 Sep 4;11:1073886. doi: 10.3389/fpubh.2023.1073886.
3. Mistry F, Gupta B, Das D. Genital dermatoses in children in a tertiary care hospital in Northeast India [Internet]. IP Indian J Clin Exp Dermatol. 2025;10(2):138-143. doi: 10.18231/j.ijced.2024.025.
4. Boero V, Cavalli R, Caia C, Berrettini A, Cetera GE, Monti E, Barbara G, Albertini GC, Restelli E, Libutti G, Motta T, Lazzari C, Vercellini P. Pediatric vulvar lichen sclerosus: Does it resolve or does it persist after menarche? Pediatr Dermatol. 2023 May-Jun;40(3):472-475. doi: 10.1111/pde.15308. Epub 2023 Mar 30.
5. Morrel B, Kampherbeek HJ, Ten Kate-Booij MJ, van der Avoort IAM, van Hees CLM, Wigny KMGJ, Burger CW, Pasmans SGMA, Lugtenberg M. Growing up with juvenile vulvar lichen sclerosus: the experiences and care needs of adult women with lichen sclerosus since childhood - a qualitative exploration. Br J Dermatol. 2024 Sep 18;191(4):556-567. doi: 10.1093/bjd/ljae203.
6. Risk factors for negative emotions in parents of children with vulvar lichen sclerosus. Dermatol Online J. 2023;29(3):24797. doi: 10.21037/tp-23-183.
7. Mansouri R, Masouye I. Vulval disease in childhood. Aust Prescr. 2005;28(4):88-90. doi: 10.18773/austprescr.2005.078.
8. Garden AS, Hernandez E. Anogenital skin diseases of childhood. Pediatr Dermatol. 1997;14(3):184-198. doi: 10.1111/j.1525-1470.1997.tb00597.x.
9. Griffith T, Hunt M, Marathe K. Vulvar skin disease in the pediatric population. Curr Opin Pediatr. 2024 Aug 1;36(4):400-405. doi: 10.1097/MOP.0000000000001370.
10. Habeshian K, Fowler K, Gomez-Lobo V, Marathe K. Guidelines for pediatric anogenital examination: Insights from our vulvar dermatology clinic. Pediatr Dermatol. 2018;35(5):693-695. doi: 10.1111/pde.13586.
11. Koumantanou C, Rallis E, Dolianitis C, et al. Microbiological findings in prepubertal and pubertal girls with vulvovaginitis. J Pediatr Adolesc Gynecol. 2022;35(5):532-537. doi: 10.1016/j.jpag.2022.04.004.
12. Fischer G, Bradford J. Vulvar lichen sclerosus. In: Paediatric Dermatology. Oxford Academic; 2010. Chapter 13. doi: 10.1093/med/9780199547999.003.0013.
13. Yates A, Akakhir L, Whitaker-Worth D. Pediatric Vulvar Lichen Sclerosus - A Review of the Literature. Dermatol Online J. 2021;27(7):13030.
14. Dalziel K, Millard PR, Wojnarowska F. The treatment of vulval lichen sclerosus with a very potent topical steroid (clobetasol propionate 0.05%) cream. Br J Dermatol. 1991;124(5):461-464. doi: 10.1111/j.1365-2133.1991.tb00626.x.
15. Cassey AM, et al. Ultrapotent topical corticosteroid treatment of childhood genital lichen sclerosus. JAMA Dermatol. 1999;135(4):525-528. doi: 10.1001/archderm.135.5.525.
16. Balakirski G, Almagout P, Novak N, et al. Lichen sclerosus: The 2023 update. Front Med (Lausanne). 2023;10:1106318. doi: 10.3389/fmed.2023.1106318.
17. Kiene P, Mempel M, Heger-Hertwig K, et al. Childhood lichen sclerosus: a long-term follow-up. Arch Dermatol. 2009;145(9):1058-1061. doi: 10.1001/archdermatol.2009.201.
18. Beck KM, Yang EJ, Sanchez IM, Liao W. Treatment of Genital Psoriasis: A Systematic Review. Dermatol Ther (Heidelb). 2018;8(4):509-525. doi: 10.1007/s13555-018-0257-y.
19. Osier E, Wang AS, Tollefson MM, Cordoro KM,

Daniels SR, Eichenfield A, Gelfand JM, Gottlieb AB, Kimball AB, Lebwohl M, Mehta NN, Paller AS, Schwimmer JB, Styne DM, Van Voorhees AS, Tom WL, Eichenfield LF. Pediatric Psoriasis Comorbidity Screening Guidelines. JAMA Dermatol. 2017;153(7):698-704. doi: 10.1001/jamadermatol.2017.0499.
20. Farajzadeh S, Khalili M, Mirmohammadkhani M, Paknazar F, Rastegarnasab F, Abtahi-Naeini B. Global clinicoepidemiological pattern of childhood vitiligo: a systematic review and meta-analysis. BMJ Paediatr Open. 2023;7(1):e001839. doi: 10.1136/bmjpo-2022-001839.
21. Pande P, Suggu SR, Bhalla M. A Rare Case of Congenital Vitiligo in a Neonate. J Clin Aesthet Dermatol. 2021;14(6 Suppl 1):S27-S29.
22. Narita T, Oiso N, Fukai K, Kabashima K, Kawada A, Suzuki T. Generalized vitiligo and associated autoimmune diseases in Japanese patients and their families. Allergol Int. 2011 Dec;60(4):505-8. doi: 10.2332/allergolint.11-OA-0303.
23. Meza-Romero R, Navarrete-Dechent C, Downey C. Molluscum contagiosum: an update and review of new perspectives in etiology, diagnosis, and treatment. Clin Cosmet Investig Dermatol. 2019 May 30;12:373-381. doi: 10.2147/CCID.S187224.
24. Dudlová A, Juriš P, Jarčuška P, Vasilková Z, Vargová V, Sumková M, Krčméry V. The Incidence of Pinworm (Enterobius Vermicularis) in Pre-school and School Aged Children in the Eastern Slovakia. Helminthologia. 2018 Oct 27;55(4):275-280. doi: 10.2478/helm-2018-0030.
25. Kerkeni Y, Thamri F, Jouini R. Management of Labial Adhesion in a Low-Income Country. Turk Arch Pediatr. 2023;58(3):339-340. doi:10.5152/TurkArchPediatr.2023.22252.
26. Abu-Alhaija H, Zayed E, Abu-Alhaija B. Anogenital Papular Lesions in Children Five Year Old and Younger: Gender Differences. Med Arch. 2020 Feb;74(1):28-33. doi: 10.5455/medarh.2020.74.28-33.
27. Liy-Wong C, Kim M, Kirkorian AY, et al. Hidradenitis Suppurativa in the Pediatric Population: An International, Multicenter, Retrospective, Cross-sectional Study of 481 Pediatric Patients. JAMA Dermatol. 2021;157(4):385–391. doi:10.1001/jamadermatol.2020.5435.
28. Lambert RA, Stein SL. Pediatric hidradenitis suppurativa: Describing care patterns in the emergency department. Pediatr Dermatol. 2023 May-Jun;40(3):434-439. doi: 10.1111/pde.15231.
29. Granese R, Calagna G, Morabito G, Carriero C, Perino A, Tonni G, Romano C. Vulvar involvement in pediatric Crohn's disease: a systematic review. Arch Gynecol Obstet. 2018 Jan;297(1):3-11. doi: 10.1007/s00404-017-4539-x.
30. Rendina S, Ferrara D, Mamone R, Isoldi S, ZeccoliniM, Esposito F. Vulvar Swelling in a 12-Year-Old Girl: An Early Manifestation of Crohn's Disease. Case Reports in Clinical Medicine. 2024;13:219-226. doi: 10.4236/crcm.2024.137025.
31. Yıldız M, Köker O, Adrovic A, Şahin S, Barut K, Kasapçopur Ö. Pediatric Behçet's disease - clinical aspects and current concepts. Eur J Rheumatol. 2020 Feb;7(Suppl1):S38-S47. doi: 10.5152/eurjrheum.2019.19121.
32. Giani T, Luppino AF, Ferrara G. Treatment Options in Pediatric Behçet's Disease. Paediatr Drugs. 2023;25(2):165-191. doi:10.1007/s40272-022-00548-5.
33. Habeshian K, Fowler K, Gomez-Lobo V, Marathe K. Guidelines for pediatric anogenital examination: Insights from our vulvar dermatology clinic. Pediatr Dermatol. 2018 Sep;35(5):693-695. doi: 10.1111/pde.13586. Epub 2018 Jul 4. PMID: 29974531.
34. Hertweck P, Yoost J. Common problems in pediatric and adolescent gynecology. Expert Review of Obstetrics & Gynecology. 2010; 5(3), 311–328. https://doi.org/10.1586/eog.10.9
35. Das A, Panda S. Use of Topical Corticosteroids in Dermatology: An Evidence-based Approach. Indian J Dermatol. 2017;62(3):237-250. doi:10.4103/ijd.IJD_169_17.
36. Crockett JL, Kim S, von Scheven E, Mathur A, Cordoro KM. Combined Pediatric Rheumatology/Dermatology Clinics: Benefits and Challenges. Pediatr Dermatol. 2025 Jan-Feb;42(1):41-46. doi: 10.1111/pde.15774.
37. Davis VJ. What the paediatrician should know about paediatric and adolescent gynecology: The perspective of a gynecologist. Paediatr Child Health. 2003 Oct;8(8):491-5. doi: 10.1093/pch/8.8.491.
38. Antonson M, Thomas S, Borucki R, Wei EX. The impact of multidisciplinary clinics in dermatology: A review. JAAD Reviews. 2024; (2):20-24. doi.org/10.1016/j.jdrv.2024.08.008.
39. ACGME Pediatric Dermatology Supplemental Guide. Accreditation Council for Graduate Medical Education.2023. https://www.acgme.org/globalassets/pdfs/milestones/pediatricdermatologysupplemental-guide.pdf.
40. Society for Pediatric Dermatology Publications. Pediatric Dermatology Journal. 2024. https://pedsderm.net/publications/pediatric-dermatology/.

INTERNATIONAL JOURNAL
of PEDIATRIC DERMATOLOGY

Special Issue, 2025
ISSN 3035-1006 online

Review

Nickel Allergy in Children and Adolescents: Between Myth and Reality

Massimo Gola[1,2] and Manfredi Magliulo[1]

[1]*Allergological and Pediatric Dermatological Unit, University of Florence and Azienda USL Toscana Centro, Florence, Italy;* [2]*G. Marconi University, Rome, Italy*

KEYWORDS

Allergic Contact Dermatitis
Nickel sensitization
Nickel allergy
Patch test
Systemic Nickel Allergy Syndrome

ABSTRACT

Nickel is a ubiquitous allergen found in many everyday objects. Hypersensitivity to nickel is the leading cause of allergic contact dermatitis in all ages, including pediatrics. Sensitization often begins in childhood and puberty, peaking between the ages of 12 and 20. Ear and body piercing have consistently been identified as the most significant risk factor for nickel sensitization in young people. The authors illustrate the main legislative regulations governing the presence of nickel in many manufactured products and cosmetics.

CORRESPONDING AUTHOR

Prof. Massimo Gola,
Allergological and Pediatric Dermatological Unit, University of Florence and Azienda USL Toscana Centro, Florence, Italy;
G. Marconi University, Rome, Italy
tel: +39.336684586
e-mail:
massimo.gola@uslcentro.toscana.it

Copyright 2025 © by World Health Academy Publishing House
This publication and/or article is for individual use only and may not be further reproduced without written permission from the copyright holder.
Unauthorized reproduction may result in financial and other penalties
DISCLOSURE: ALL AUTHORS REPORT NO CONFLICTS OF INTEREST RELEVANT TO THIS ARTICLE.

Introduction

Nickel (Ni), a silvery-white transition element, ranks as the fourth most widely used metal worldwide, after iron, chromium, and lead. With atomic number 28, it belongs to group 10 of the periodic table and is commonly found in the Earth's crust in various mineral forms such as garnierite and niccolite. It is also present in soils as a contaminant from industrial processes. Nickel's unique physicochemical properties—including low atomic mass, high chemical reactivity, and pronounced hydrophobicity—render it a highly potent hapten. As such, it can bind covalently to endogenous proteins, creating immunogenic complexes capable of triggering a delayed-type hypersensitivity reaction mediated by T lymphocytes.

Approximately 65% of nickel is used in the production of stainless steel, while smaller percentages are employed in non-ferrous alloys, surface plating (nickel plating), and various other sectors including construction, electronics, automotive components, and medical instrumentation. The pervasive presence of nickel in everyday items—ranging from jewelry and clothing accessories to coins, orthodontic materials, and even cosmetics—has resulted in widespread environmental exposure. This ubiquity underlies its status as the most prevalent contact allergen in both pediatric and adult populations, representing a major concern in dermatological and allergological practice.

Allergic Contact Dermatitis: incidence, pathogenesis, and clinical expression

Nickel-induced allergic contact dermatitis (ACD) is a prototypical form of Type IV hypersensitivity, as classified by Gell and Coombs. It is characterized by the development of pruritic, eczematous lesions following dermal exposure to the metal in sensitized individuals. Unlike irritant contact dermatitis (ICD), which results from direct cytotoxic effects without immune involvement, ACD reflects an antigen-specific, cell-mediated immune response. Sensitization occurs when antigen-presenting cells such as Langerhans cells internalize nickel-protein conjugates and migrate to the regional lymph nodes, where they activate naïve T cells. Re-exposure elicits clonal expansion of memory T cells and the release of pro-inflammatory cytokines, most notably interferon gamma (IFN-γ) and tumor necrosis factor alpha (TNF-α), culminating in the cutaneous inflammatory cascade.

Percutaneous absorption of nickel is facilitated by a number of cofactors including humidity, perspiration, mechanical friction, elevated temperature, and occlusion, all of which compromise the integrity of the epidermal barrier, particularly the stratum corneum. Clinically, ACD due to nickel presents as acute erythema, vesiculation, and edema or, in chronic forms, lichenification, desquamation, and fissuring (Fig. 1). Involvement of visible or functionally important areas such as the hands can significantly impair quality of life, leading to functional limitations, occupational disability, and psychosocial distress.

Fig. 1. *Allergic contact dermatitis caused by nickel-containing costume jewelry worn on the wrist.*

Epidemiological insights and risk determinants

Epidemiological surveys conducted across Europe estimate the prevalence of nickel sensitization in females to range from 8% to 15%, while in males it remains lower, between 1% and 3%. The gender disparity is attributed to behavioral and cultural factors, particularly the early and frequent use of nickel-containing jewelry among adolescent girls. Sensitization often begins in childhood, with several studies reporting increasing prevalence during puberty, peaking between the ages of 12 and 20.

The practice of ear and body piercing has been consistently identified as the most significant risk factor for nickel sensitization in young individuals. During the post-piercing re-epithelialization phase, the prolonged occlusive contact between healing tissue and nickel-laden earrings fosters hapten penetration and immune priming. Notably, data from Italian dermatology clinics indicate a sensitization rate of 15% among pierced adolescents, compared to only 2% among those without piercings. Moreover, the risk increases with the number of piercings, demonstrating a dose-response relationship.

Regulatory policies and exposure thresholds

In an effort to curb the public health burden of nickel-induced contact allergy, the European Union enacted Directive 94/27/EC, later incorporated into the REACH regulation, which limits the permissible nickel release from items intended for prolonged skin contact to 0.5 μg/cm²/week, and 0.2 μg/cm²/week for objects intended to be inserted into pierced skin. Despite this regulatory framework, numerous sources of exposure remain unregulated or poorly controlled, particularly in non-industrial contexts.

Metallic currency, such as 1- and 2-euro coins composed of nickel-brass or nickel-copper alloys, have been shown to release quantities of nickel vastly exceeding regulated thresholds. In nickel-sensitized individuals, repeated contact with such objects, especially in the presence of sweat—can elicit flare-ups of dermatitis. Other unregulated items include metallic tools, buttons, keys, orthopedic devices, orthodontic appliances, and various electronic components. Additionally, cosmetics - especially those containing inorganic pigments like iron oxides - can be inadvertently contaminated with trace amounts of nickel. While the regulatory limit for nickel in cosmetics is 5 ppm, products such as children's toy makeup often fail to comply.

The dimethylglyoxime spot test, in combination with ammonium hydroxide, remains a reliable, simple, and cost-effective method for detecting free nickel release, producing a pink coloration upon contact with nickel concentrations exceeding 10 ppm.

Systemic Nickel Allergy Syndrome (SNAS)

In addition to localized ACD, sensitized individuals may exhibit systemic reactions to dietary nickel intake, a condition known as Systemic Nickel Allergy Syndrome (SNAS). In these cases, the ingestion of nickel-rich foods or the use of cookware that leaches nickel into food may provoke widespread symptoms. Clinical manifestations include dyshidrotic hand eczema, nummular and papulovesicular eruptions, urticaria, purpuric lesions, and extra-cutaneous symptoms such as headache, fatigue, pruritus, bloating, diarrhea, and other gastrointestinal disturbances.

The underlying immunological mechanisms are complex and likely involve both Type I (IgE-mediated) and Type IV (T cell-mediated) pathways. The daily oral threshold associated with symptom reactivation is estimated to range between 0.3 and 0.6 mg of elemental nickel. High-nickel foods include cocoa, legumes, nuts, soy, whole grains, spinach, tomatoes, and certain seafood.

Diagnosis and clinical management

The cornerstone of diagnosis is epicutaneous patch testing, typically performed with 5% nickel sulfate in petrolatum (Fig. 2). For environmental sources, spot tests can identify nickel release from suspect items. In cases of SNAS, the implementation of a low-nickel diet, maintained under medical supervision for at least 8 to 12 weeks, may provide clinical benefit, though outcomes vary among patients.

In refractory or severe cases, experimental protocols involving oral desensitization with controlled micro-

doses of nickel have been proposed. These aim to induce immunological tolerance via gradual modulation of T-cell reactivity; however, such approaches remain investigational and are not yet standardized in clinical practice.

Fig. 2. *Positive patch test reaction to nickel sulfate 5%, indicating nickel allergy.*

References

1. Bernstein J, Keller L, Pacheco K. Updates in Metal Allergy: A Review of New Pathways of Sensitization, Exposure, and Treatment. Curr Allergy Asthma Rep. 2025;25(1):28.
2. Bonamonte D, De Marco A, Ciccarese G, Romita P, Giancaspro G, Ambrogio F, Foti C. Contact Allergy in Atopic Dermatitis and Psoriasis: A Retrospective Study. Diagnostics (Basel). 2025;15(6):766.
3. Hilewitz D, Trattner A, Hackett A, Raviv A, Noyman Y, Endelman S, Slodownik D, Daniely D, Friedland R, Mimouni D, Snast I. Epidemiology of Sensitivity to Nickel, Cobalt and Chromium in Israel: A Retrospective Cohort Study. Contact Dermatitis. 2025 Jun 3.
4. Ferrari C, Somma G, Giovinazzo V, Iarossi M, Treglia M, Pallocci M, Di Giampaolo L, Magrini A, Coppeta L. The Influence of Occupational Factors on Contact Dermatitis in Symptomatic Healthcare Workers: A Patch Test Study. Diseases. 2025;13(3):77.
5. Niu JR, Zhou H, Xia X, Tian R. Analysis of patch test results in 716 pediatric patients with type IV hypersensitivity dermatosis. Arch Dermatol Res. 2025;317(1):515
6. Hsu JW, Matiz C, Jacob SE. Nickel Allergy: Localized, Id, and Systemic Manifestations in Children. Pediatr Dermatol. 2011;28(3):276–280.
7. Schram SE, Warshaw EM, Laumann AE. Nickel hypersensitivity: a clinical review and call to action. Int J Dermatol. 2010;49(2):115–125.
8. Darlenski R, Kazandjieva J, Pramatarov K. The many faces of nickel allergy. Int J Dermatol. 2012;51(5):523–530.
9. Ricciardi L, Arena A, Arena E, et al. Systemic Nickel Allergy Syndrome: Epidemiological Data from Four Italian Allergy Units. Int J Immunopathol Pharmacol. 2014;27(1):131–136.

INTERNATIONAL JOURNAL
of PEDIATRIC DERMATOLOGY

Special Issue, 2025
ISSN 3035-1006 online

Narrative Review

Which Foods Can Be Beneficial in Dermatology?

Diego Peroni[1], Alessia Pieri[1] and Alessandra Buononato[1]

[1]*Department of Clinical and Experimental Medicine, Section of Pediatrics, University of Pisa, Pediatrics Unit, AOUP, Pisa, Italy*

KEYWORDS

Atopic dermatitis,
Prevention,
Diet,
Nutrition,
Breast milk,
Vitamin D,
Probiotics,
Omega-3-LCPUFA

ABSTRACT

The authors discuss the potential role of specific nutrients in the prevention of atopic dermatitis. They highlight the importance of introducing micronutrients to promote favorable immunomodulation in children affected by this condition. Finally, they emphasize the need for consensus among specialists regarding the execution of allergy testing, as well as the timing of dietary introduction of solid foods, eggs, and peanuts.

CORRESPONDING AUTHOR

Diego Peroni,
Department of Clinical and Experimental Medicine, Section of Pediatrics, University of Pisa,
Pediatrics Unit, AOUP, Pisa, Italy
e-mail: diego.peroni@unipi.it

Copyright 2025 © by World Health Academy Publishing House
This publication and/or article is for individual use only and may not be further reproduced without written permission from the copyright holder.
Unauthorized reproduction may result in financial and other penalties
DISCLOSURE: ALL AUTHORS REPORT NO CONFLICTS OF INTEREST RELEVANT TO THIS ARTICLE.

The role of nutrition in prevention in pediatric dermatology

Promoting a balanced, healthy, and varied diet from pregnancy through childhood can be helpful in preventing atopic dermatitis and childhood asthma (1). Nutrients such as vitamin D, probiotics, and omega-3-LCPUFA fatty acids have been shown to be effective in the literature. Both during pregnancy, especially in the third trimester, and after birth, while continuing to provide the child with a diet rich in protective nutrients, the mother can supplement the diet with vitamin D, probiotics, and omega-3-LCPUFA supplements, at high doses, to reduce the risk of developing atopic dermatitis and prevent childhood asthma (1-3).

Food allergies and atopic dermatitis

The most complete and safe food for newborns is breast milk. Through breastfeeding, nutrients and many functional elements are passed on to the baby, helping to shape a developing immune system. It is therefore important to reinforce the value and necessity of breastfeeding. In infants at high risk of developing atopic dermatitis, a risk primarily determined by family history, or who have already developed dermatitis in the first six months of life, weaning should involve regular introduction of foods, even the most allergenic ones, following appropriate timing as with all other infants. It should be done no earlier than 5-6 months, but no later than the seventh month. During this phase of complementary feeding, food allergy screening is indicated only in a few cases, and only in cases of dermatitis that have already appeared and is more severe. Elimination diets are widely discouraged, not only to avoid nutritional deficiencies but also because of the risk of developing new allergies. According to Anglo-Saxon studies, introducing allergenic foods such as eggs and peanuts in small amounts and at appropriate times, such as between 6 and 8 months of age, can help reduce the risk of allergies. Although this is more difficult in our population, the idea of introducing allergens during a phase of immune system development, which corresponds to the complementary feeding phase, is appealing in the perspective that can induce greater tolerance (4).

Micronutrients and immune modulation

Vitamins and micronutrients are essential for children with dermatitis. Ensuring an adequate intake of vitamins C, D, E, magnesium, selenium, zinc, and omega-3s is recommended for immune health and disease prevention or treatment. Ensure your child's diet includes foods rich in essential vitamins and minerals, such as citrus fruits for vitamin C, fish for omega-3-LCPUFA fatty acids and vitamin D, and nuts and seeds for magnesium and zinc. If dietary intake is scarce, supplementation is needed. This can help maintain a healthy immune system and help treat dermatitis, where nutritional deficiencies of trace elements and vitamins are often common (5, 6). Some deficiencies, in fact, are characterized by dermatological manifestations. It is therefore necessary to raise awareness of the importance of preventing vitamin C and B3 deficiencies to avoid diseases such as scurvy and pellagra, which are extremely rare today but can recur. Educating parents on the importance of a balanced diet to prevent vitamin deficiencies is therefore essential for the pediatrician. For example, including fresh fruits and vegetables to prevent scurvy (vitamin C deficiency) and niacin-rich foods such as meat and whole grains to prevent pellagra (vitamin B3 deficiency). But this is an opportunity to reiterate how a varied, free, and rich diet is important for both children and parents.

Clinical recommendations and specialist collaboration

A child with atopic dermatitis is usually treated by a series of specialists: family pediatricians, dermatologists and pediatric allergologists. Always remembering that this is constitutional condition, all specialists involved should approach the disease uniformly. Specific allergy tests should be performed only in very select cases, paying close attention to the test results. It is necessary to adopt targeted therapies for the management of persistent atopic dermatitis, but also to distinguish between allergies and intolerances and avoid unnecessary and often dangerous strict diets for growing children. Therefore, full collaboration between specialists

such as allergists and dermatologists is necessary to perform specific allergy tests indicated and develop increasingly personalized treatment plans for children with persistent atopic dermatitis. It is essential to avoid unnecessary restrictive diets and clearly distinguish between allergies and intolerances (7).

From a practical standpoint, solid foods should be introduced after 6 months of age, never at 4 months, based on the baby's chewing ability and neuromotor development. Introduce solid foods such as pureed vegetables and fruit around 6 months, ensuring the baby is ready. Offer cooked and uncooked eggs as the first solid food and introduce peanuts during weaning in an appropriate form even at high risk children, performing the skin prick tests only in patients with severe atopic dermatitis.

References

1. Brustad N, Chawes B. Vitamin D Primary Prevention of Respiratory Infections and Asthma in Early Childhood: Evidence and Mechanisms. J Allergy Clin Immunol Pract. 2024; 12(7):1707-1714.
2. Brustad N, Wang T, Chen L, Kaiser H, Gomes B, Klein A, Vahman N, Skov L, Stokholm J, Schoos AM, Bønnelykke K, Chawes B. Prenatal high-dose vitamin D supplementation and childhood atopic dermatitis until age 6 years: A secondary analysis of a randomized clinical trial. Br J Dermatol. 2025; 193(4):775-777.
3. Trikamjee T, Comberiati P, D'Auria E, Peroni D, Zuccotti GV. Nutritional Factors in the Prevention of Atopic Dermatitis in Children. Front Pediatr. 2021; 8:577413.
4. Vassilopoulou E, Comotti A, Douladiris N, Konstantinou GN, Zuberbier T, Alberti I, Agostoni C, Berni Canani R, Bocsan IC, Corsello A, De Cosmi V, Feketea G, Laitinen K, Mazzocchi A, Monzani NA, Papadopoulos NG, Peroni DG, et al. A systematic review and meta-analysis of nutritional and dietary interventions in randomized controlled trials for skin symptoms in children with atopic dermatitis and without food allergy: An EAACI task force report. Allergy. 2024; 79(7):1708-1724.
5. Peroni DG, Piacentini GL, Cametti E, Chinellato I, Boner AL. Correlation between serum 25-hydroxyvitamin D levels and severity of atopic dermatitis in children. Br J Dermatol. 2011; 164(5):1078-82.
6. Peroni DG, Hufnagl K, Comberiati P, Roth-Walter F. Lack of iron, zinc, and vitamins as a contributor to the etiology of atopic diseases. Front Nutr. 2023; 9:1032481.
7. Peroni DG, Campoy C, Verduci E. Editorial: Role of early life nutrition in immunomodulation and microbiota development. Front Nutr. 2023; 10:1266725.

INTERNATIONAL JOURNAL
of PEDIATRIC DERMATOLOGY

Special Issue, 2025
ISSN 3035-1006 online

Review

New Therapies for Moderate-to-Severe Atopic Dermatitis in Pediatric Patients

Andrea Conti[1] and Federico Tartari[1]

[1]*Dermatologic Unit, Department of Surgery, Infermi Hospital of Rimini, AUSL Romagna, Rimini, Italy*

KEYWORDS

Atopic Dermatitis
Skin barrier alterations
Dysregulated immune activity
IL13 inhibitors
JAK inhibitors
Crisaborole
Ruxolitinib
Tapinarof
Nemolizumab

CORRESPONDING AUTHOR

Andrea Conti,
Dermatologic Unit, Department of Surgery, Infermi Hospital of Rimini, AUSL Romagna, Viale Settembrini 2, 47923 Rimini (RN), Italy
e-mail: a.conti.dermo@gmail.com

ABSTRACT

In pediatric patients with severe atopic dermatitis, novel therapeutic options have recently become available - options that were not accessible until a few years ago. The authors outline the principal agents currently approved for systemic treatment, as well as those undergoing advanced clinical investigation.

Copyright 2025 © by World Health Academy Publishing House
This publication and/or article is for individual use only and may not be further reproduced without written permission from the copyright holder.
Unauthorized reproduction may result in financial and other penalties
DISCLOSURE: ALL AUTHORS REPORT NO CONFLICTS OF INTEREST RELEVANT TO THIS ARTICLE.

Introduction

Atopic dermatitis (AD), is a chronic inflammatory skin condition that affects 15%–20% of children and its pathophysiology involve genetical factors, alterations of skin barrier functions and dysregulated immune activity (1, 2). Severe clinical manifestation of AD are characterized by diffuse eczema lesions, intense itch and a negative impact on quality of life (QoL); the severity of the disease in calculated by the Eczema Area and Severity Index (EASI) and pruritus Numerical Rating Scale (NRS) (3) (Fig. 1-3). Most recent studies have demonstrated the role of Interleukin 13 (IL13) as a key cytokine in the pathogenesis of AD and in Th2 cell-mediated responses (2). This has led to the development of new systemic therapies that can effectively control disease symptoms over the long term. At this moment, in Italy are available tree IL 13 inhibitors and tree Janus Kinase JAK inhibitors for the treatment of moderate-to-severe AD.

Fig. 1. *Clinical manifestations of AD.*

Fig. 2. *Clinical manifestations of AD.*

Fig. 3. *Clinical manifestations of AD.*

New systemic treatment for moderate-to-severe AD

In Italy, the treatment of moderate-to-severe AD with the following therapies is indicated in patients with EASI > 24 or Involvement of visible or sensitive areas, RNS > 7 and CDLQI > 10 (Table I).

Table I. *Therapies for moderate-to-severe AD in paediatric patients.*

CLASS	GENERIC NAME	TARGET	METHOD OF ADMINISTRATION
IL4/13 inhibitor	Dupilumab	IL4 and IL13	Subcutaneous
IL13 inhibitor	Tralokinumab	IL13	Subcutaneous
	Lebrikizumab	IL13	Subcutaneous
JAK inhibitor	Upadacitinib	JAK1, JAK1/3	Oral
	Baricitinib	JAK1, JAK2	Oral
	Abrocitinib	JAK1	Oral

IL13 inhibitors

IL-13 inhibitors are a class of biological drugs that target IL-13, which is involved in the persistent inflammation of the skin in patients with atopic AD. They are characterized by an high level of efficacy in EASI 75; the most common side effects are represented by injection site reactions and conjunctivitis. The administration of the treatment is by subcutaneous injection.

Dupilumab

It is a human monoclonal antibody that acts as an IL4 and IL13 receptor antagonist. It is approved for the treatment of moderate-to-severe AD in children aged from six months. The efficacy in paediatric population showed an EASI 75 response rates around 79.4% to 85.8% by week 16 to week 52 without severe adverse events (AE) (4). From a practical standpoint, solid foods should be introduced after 6 months of age, never at 4 months, based on the baby's chewing ability and neuromotor development. Introduce solid foods such as pureed vegetables and fruit around 6 months, ensuring the baby is ready. Offer cooked and uncooked eggs as the first solid food and introduce peanuts during weaning in an appropriate form even at high risk children, performing the skin prick tests only in patients with severe atopic dermatitis.

Tralokinumab

It is a human monoclonal antibody that works by blocking IL-13 and it is approved for moderate-to-severe AD in patients aged 12 and older combined to the application of topical corticosteroids. In clinical trials, 57.8% of adolescent patients achieving EASI-75 by week 52 without severe AE (5).

Lebrikizumab

It is a humanized monoclonal antibody that acts blocking IL-13 and it is approved for moderate-to-severe AD in patients aged 12 and older. Clinical trials demonstrated the efficacy of Lebrikizumab: the EASI mean percentage improvement from baseline to Week 52 was 86.0% (6).

JAK inhibitors

JAK inhibitors are a class of oral drugs medications that acts by blocking Janus kinase (JAK) enzymes, which disrupts the JAK-STAT signalling pathway that transmits signals related to inflammation. This class of drugs are used in several immune-mediated inflammatory diseases. JAKs are intracellular enzymes that activate cytokine-mediated signals through the JAK-STAT metabolic pathway, which is involved in a wide range of cellular processes, including inflammatory responses, haematopoiesis, and immune surveillance.

The JAK enzyme family includes: JAK1, JAK2, JAK3, and TYK2 (tyrosine kinase 2), which act in pairs to phosphorylate and activate signal transducers and activators of transcription (STATs) at various levels and with different selectivity. JAK1 is primarily involved in inflammatory cytokine signalling, JAK2 is predominantly involved in signals for red blood cell maturation and JAK3 plays a role in immune surveillance and lymphocyte function. This class of drugs demonstrated high efficacy in the treatment of AD; most common side effects are represented by upper respiratory infections, headache, nausea, diarrhoea, acne, elevated cholesterol levels, and changes in blood cell counts. The administration of the treatment is orally.

Upadacitinib

It acts blocking JAK 1 and JAK 1/3 activity. It is approved for moderate-to-severe AD in patients aged 12 and older. The efficacy and safety were evaluated in randomized clinical trial involving 542 adolescents. At week 76, EASI-75 was achieved in 84.4% to 89.1% of patients (dose 15 mg/day) and in 82.7% to 96.1% (dose 30 mg/day) (7).

Baricitinib

It acts blocking JAK 1 and JAK 2 activity; it is approved for moderate-to-severe AD in patients aged 2 and older. The efficacy and safety were evaluated in randomized clinical trial involving 483 patients. At week 16, patients treated with a dose of 4 mg/day achieved EASI-75 and EASI 90 in 52.5% and 30% of cases respectively (8).

Abrocitinib

It acts blocking JAK 1 activity; It is approved for moderate-to-severe AD in patients aged 12 and older. The efficacy and safety were evaluated in randomized clinical trial involving 124 patients. EASI 75 was achieved by 68% and 72% of patients treated with a dose of 100 mg/day and 200 mg/day (9).

New drugs in the pipeline

Continuous progress in the study of pathogenesis of AD, in addition to currently approved drugs, has allowed for the development of new molecules that are still in the study phase and will likely be available soon. Here are some drugs in advanced stages of clinical trials.

Crisaborole

It acts as an inhibitor of Phosphodiesterase 4 (PDE4). Efficacy outcomes of the treated individuals who achieved ISGA success (clear (0)) on day 29. ISGA (Investigator Static Global Assessment). Several studies have also evaluated the topical use of crisaborole in terms of efficacy and safety in paediatric patients (10).

Ruxolitinib

It acts as JAK 1 and 2 inhibitors. In the TRuE-AD studies, patients 12 years of age and older with AD were randomized in a 2:2:1 ratio to apply 1.5% ruxolitinib cream twice daily, 0.75% ruxolitinib cream, or a vehicle continuously for 8 weeks, with benefits lasting up to 1 year of therapy (11).

Tapinarof

Tapinarof is a topical aryl hydrocarbon receptor (AhR) agonist. In two Phase 3 studies, tapinarof 1% cream, applied once daily, demonstrated significant efficacy and was well-tolerated in patients as young as 2 years old with AD (12).

Nemolizumab

Nemolizumab is a subcutaneously administered humanized monoclonal antibody that blocks the interleukin-31 alpha receptor (IL-31RA). Two phase III clinical trials demonstrated the safety and the efficacy of long-term treatment with nemolizumab for paediatric patients with AD, over 68 weeks of treatment (13).

Conclusions

The current therapeutic landscape for treating AD is constantly and rapidly evolving. Even for paediatric patients, there are now treatment options that were not available just a few years ago. Furthermore, the development of new therapies already in advanced stages of study will surely make it possible to effectively control the symptoms of this chronic condition.

References

1. Asher MI, Montefort S, Bjorksten B, Lai CK, Strachan DP, Weiland SK, et al. Worldwide time trends in the prevalence of symptoms of asthma, allergic rhinoconjunctivitis, and eczema in childhood: ISAAC phases one and three repeat multicountry cross- sectional surveys. Lancet. 2006;368:733–43.
2. David Boothe W, Tarbox JA, Tarbox MB. Atopic dermatitis: pathophysiology. Adv Exp Med Biol. 2017;1027:21–37.
3. Hanifin JM, Thurston M, Omoto M, Cherill R, Tofte SJ, Graeber M. The eczema area and severity index (EASI): assessment of reliability in atopic dermatitis. EASI Evaluator Group. Exp Dermatol. 2001 ;10(1):11-8.
4. Amy S. Paller, Elaine C. Siegfried, Michael J. Cork, Kenji Kabashima, Peter D. Arkwright, Edyta Gębska, Zhen Chen, Joseph Zahn, Ana B. Rossi. Efficacy and safety of dupilumab in pediatric patients aged 6 months to 11 years with erythrodermic atopic dermatitis: A post-hoc analysis of 3 clinical trials, J. Am. Acad. Dermatol. 2025; 93(4):1066-1070. doi.org/10.1016/j.jaad.2025.05.1422.
5. Paller AS, Flohr C, Cork M, Bewley A, Blauvelt A, Hong HC, Imafuku S, Schuttelaar MLA, Simpson EL, Soong W, Arlert P, Lophaven KW, Kurbasic A, Soldbro L, Vest NS, Wollenberg A. Efficacy and Safety of Tralokinumab in Adolescents With Moderate to Severe Atopic Dermatitis: The Phase 3 ECZTRA 6 Randomized Clinical Trial. JAMA Dermatol. 2023;159(6):596-605. doi: 10.1001/jamadermatol.2023.0627.
6. Paller AS, Flohr C, Eichenfield LF, Irvine AD, Weisman J, Soung J, Pinto Correia A, Natalie CR, Rodriguez Capriles C, Pierce E, Reifeis S, Gontijo Lima R, Armengol Tubau C, Laquer V, Weidinger S. Safety and Efficacy of Lebrikizumab in Adolescent Patients with Moderate-to-Severe Atopic Dermatitis: A 52-Week, Open-Label, Phase 3 Study. Dermatol Ther (Heidelb). 2023;13(7):1517-1534. doi: 10.1007/s13555-023-00942-y.
7. Paller AS, Mendes-Bastos P, Siegfried E, Eichenfield LF, Soong W, Prajapati VH, Lio P, Simpson EL, Raymundo EM, Suravaram S, Hu X, Yang Y, Huang X, Calimlim BM, Platt AM, Su JC, Zheng M, Yamamoto-Hanada K, Teixeira HD, Irvine AD. Upadacitinib in Adolescents With Moderate to Severe Atopic Dermatitis: Analysis of 3 Phase 3 Randomized Clinical Trials Through 76 Weeks. JAMA Dermatol. 2024;160(12):1304-1313. doi: 10.1001/jamadermatol.2024.3696.
8. Torrelo A, Rewerska B, Galimberti M, Paller A, Yang CY, Prakash A, Zhu D, Pontes Filho MAG, Wu WS, Eichenfield LF. Efficacy and safety of baricitinib in combination with topical corticosteroids in paediatric patients with moderate-to-severe atopic dermatitis with an inadequate response to topical corticosteroids: results from a phase III, randomized, double-blind, placebo-controlled study (BREEZE-AD PEDS). Br J Dermatol. 2023; 189(1):23-32. doi: 10.1093/bjd/ljad096.
9. Eichenfield LF, Flohr C, Sidbury R, Siegfried E, Szalai Z, Galus R, Yao Z, Takahashi H, Barbarot S, Feeney C, Zhang F, DiBonaventura M, Rojo R, Valdez H, Chan G. Efficacy and Safety of Abrocitinib in Combination With Topical Therapy in Adolescents With Moderate-to-Severe Atopic Dermatitis: The JADE TEEN Randomized Clinical Trial. JAMA Dermatol. 2021;157(10):1165-1173. doi: 10.1001/jamadermatol.2021.2830.
10. Jianhua You, Huanmei Li, Zhongyun Wang, Yunfei ZhaoEvaluating Efficacy and Safety of Crisaborole in Managing Childhood Mild to Moderate Atopic Dermatitis: A Systematic Review and Meta-Analysis. B J Hosp Med. 2025; 86(1):1-19.
11. Simpson EL, Augustin M, Thaçi D, Misery L, Armstrong AW, Blauvelt A, Papp KA, Szepietowski JC, Boguniewicz M, Kwatra SG, Kallender H, Sturm D, Ren H, Kircik L. Ruxolitinib Cream Monotherapy Improved Symptoms and Quality of Life in Adults and Adolescents with Mild-to-Moderate Atopic Dermatitis: Patient-Reported Outcomes from Two Phase III Studies. Am J Clin Dermatol. 2025; 26(1):121-137. doi: 10.1007/s40257-024-00901-z.
12. Simpson EL, Hebert AA, Browning J, Serrao RT, Sofen H, Brown PM, Piscitelli SC, Rubenstein DS, Tallman AM. Tapinarof Improved Outcomes and Sleep for Patients and Families in Two Phase 3 Atopic Dermatitis Trials in Adults and Children. Dermatol Ther (Heidelb). 2025;15(1):111-124. doi: 10.1007/s13555-024-01318-6.
13. Igarashi A, Katsunuma T, Nagano Y, Komazaki H. Long-term (68 weeks) administration of nemolizumab in paediatric patients aged 6-12 years with atopic dermatitis with moderate-to-severe pruritus: efficacy and safety data from a phase III study. Br J Dermatol. 2025;192(5):837-844. doi: 10.1093/bjd/ljae458.

INTERNATIONAL JOURNAL
of PEDIATRIC DERMATOLOGY

Special Issue, 2025
ISSN 3035-1006 online

Case Report

Eye for an Eye… Herpes Zoster Ophthalmicus in Two Children

Maddalena Milioni[1]

[1]*Pediatrician, AUSL Umbria 1, Italy*

KEYWORDS

Herpes
VZV
Shingles
Zoster ophthalmicus
Conjunctival hyperemia
Ocular pain
Acyclovir

ABSTRACT

The author reports two cases of ophthalmic herpes zoster, both associated with conjunctival hyperemia, in two children aged 11 and 5 years who had received only the first dose of varicella-zoster virus (VZV) vaccination at 15 months of age. In both cases, the clinical presentation was highly suggestive for diagnosis, and prompt therapeutic intervention successfully prevented ocular complications.

CORRESPONDING AUTHOR

Maddalena Milioni,
Pediatrician,
AUSL Umbria 1,
Italy
e-mail: dottoressamilioni@gmail.com

Copyright 2025 © by World Health Academy Publishing House
This publication and/or article is for individual use only and may not be further reproduced without written permission from the copyright holder.
Unauthorized reproduction may result in financial and other penalties
DISCLOSURE: ALL AUTHORS REPORT NO CONFLICTS OF INTEREST RELEVANT TO THIS ARTICLE.

Introduction

Herpes zoster ophthalmicus (HZO) is generally known as a disease that affect the elderly and immunocompromised people, but it can also affect children. It's incidence in the pediatric population is low and has dramatically declined since the varicella vaccination program was being introduced. Infection before 12 months of age as well as intrauterine exposure represent significant risk factors for the development of infantile zoster. In case of clinical suspect of HZO in a child, an early diagnosis and a prompt antiviral treatment are essential for reducing ocular and systemic morbidity.

Clinical case n. 1

An 11-year-old boy with no notable pathological history consulted the pediatrician office due to a painful eruption affecting the left periocular area for a day. His father had a recurrence of Herpes simplex type 1 and he was afraid to have been infected.

As for his personal history, he had been vaccinated according to the Italian vaccination schedule only with the first dose (against the varicella zoster virus) at the age of 15 months and he presented the disease at the age of 5, requiring outpatient care and symptomatic treatment.

At the first medical consultation he presented few grouped vesicles on erythematous base confined to the cutaneous distribution of the Maxillary division of Trigeminal nerve, without ocular involvement (Fig. 1).

Fig. 1. *Erythema and vesicles near the left external canthus of the eye, innervation territory of the maxillary branch of the trigeminal nerve.*

He was immediately treated with oral acyclovir but after 24 hours he developed mild conjunctival hyperemia with ocular lacrimation and local pain suggesting a possible Herpes zoster ophthalmicus (HZO). So he was referred to the emergency department for a comprehensive eye examination that revealed a mild ocular involvement without signs of keratitis or uveitis. Follow-up one week later showed complete resolution of the rash and of the ocular signs.

Clinical case n. 2

After only a month, another boy aged 5 years presented with a vesicular rash of the right eye periocular region, nearby the lower eyelid. As for his personal history, he had been vaccinated according to the Italian vaccination schedule only with the first dose (against the varicella zoster virus) at the age of 15 months. 4 years ago, he developed a herpetic gingivostomatitis and his mother had also a recurrence of Herpes simplex type 1.

Such as the first clinical case, at the first medical consultation, he presented grouped vesicles on erythematous base confined to the cutaneous distribution of the Maxillary division of Trigeminal nerve, without ocular involvement (Fig. 2).

Fig. 2. *Erythematous-vesicular lesions in the innervation territory of the second branch of the trigeminal nerve.*

He was immediately treated with oral acyclovir but after 72 hours he developed intense ocular pain with moderate conjunctival hyperemia and lacrimation suggesting a possible HZO (Fig. 3). So he was referred to the emergency department for an eye examination that revealed a mild ocular involvement without signs of keratitis or uveitis. Follow-up two week later showed a complete resolution.

Fig. 3. *Associated conjunctival hyperemia.*

Discussion

Herpes zoster (shingles) is caused by a reactivation of the varicella zoster virus (VZV), which, after the initial infection, becomes latent and persists in sensory dorsal root ganglia and cranial nerve ganglia. Incidence of HZO in the pediatric population is low, with rates of 4.8 per 100,000 in ages 0–10 and 7.8 per 100,000 in ages 11–20 (1). Varicella infection before 12 months of age is a significant risk factor for developing childhood zoster. Moreover, intrauterine exposure to varicella is a risk for the development of Herpes zoster (HZ) in infants and young children (2).

Even if an immunocompromised state can predispose children to the development of HZO, most of cases occurred in immunocompetent children but a lot of studies suggest that the incidence of pediatric HZ has dramatically declined since 1998, as the varicella vaccination program was being introduced and was maturing (3).

Diagnosis of HZO in children is primarily clinical, based on the characteristic unilateral vesicular rash in the distribution of the trigeminal nerve and associated local symptoms (red eye, excessive tearing, eye pain, blurred

vision, photophobia, and rarely decreased visual acuity). Therefore, laboratory testing is suggested in case of uncertain diagnosis (4).

Skin lesions caused by Herpes Zoster infection in children must be differentiated from Herpes Simplex type 1 and 2 infection, contact dermatitis, folliculitis, Impetigo, Dermatitis herpetiformis, drug eruptions, insect bites.

The most recent guidelines on the management of HZ suggest against initiating an antiviral medication in children in the absence of the risk of complications, but HZ of the head and/or of the neck area represent a risk factor for complicated HZ so in this case the initiation of an antiviral medication is strongly recommended (5). Children with HZO generally have a completely resolution of symptoms with a good vision recovery if they are promptly treated, but rarely HZO can cause complications in the orbit and ocular adnexa so a log-term follow-up is required.

Conclusions

HZO is generally known as a disease that affect the elderly and immunocompromised people, but it can also affect children, so in case of clinical suspect of HZO in a child, an early diagnosis and a prompt antiviral treatment are essential for reducing ocular and systemic morbidity. In case of ocular complications, an ophthalmologic long-term follow-up is also required. More systematic studies are needed to define the incidence of HZO in children and appropriate treatment and follow-up protocols for the care of pediatric HZO.

References

1. Kong CL, Thompson RR, Porco TC, Kim E, Acharya NR. Incidence rate of herpes zoster ophthalmicus: a retro-spective cohort study from 1994 through 2018. Ophthalmology. 2020;127:324–330.
2. Hakim FE, Riaz K, Farooq A. Pediatric herpes zoster ophthalmicus: a systematic review. Graefes Arch Clin Exp Ophthalmol. 2023:261(8):2169-2179.
3. Harpaz R, Leung JW. The epidemiology of Herpes Zoster in the United States during the era of varicella and Herpes Zoster vaccines: changing patterns among children. Clin Infect Dis. 2018;69(2): 345-347.
4. Werner RN, Nikkels AF , Marinović B et al. European consensus-based (S2k) Guideline on the Management of Herpes Zoster - guided by the European Dermatology Forum (EDF) in cooperation with the European Academy of Dermatology and Venereology (EADV), Part 1: Diagnosis. J Eur Acad Dermatol Venereol. 2017;31(1):9-19.
5. Werner RN, Nikkels AF , Marinović B et al. European consensus-based (S2k) Guideline on the Management of Herpes Zoster - guided by the European Dermatology Forum (EDF) in cooperation with the European Academy of Dermatology and Venereology (EADV), Part 2: Treatment. J Eur Acad Dermatol Venereol. 2017;31(1):20-29.

INTERNATIONAL JOURNAL
of PEDIATRIC DERMATOLOGY

Special Issue, 2025
ISSN 3035-1006 online

Case Report

Persistent Congenital Hemangioma

Amalia Licordari[1]

[1]*Family Pediatrician, Reggio Calabria, Italy*

KEYWORDS

Vascular lesion
Infantile Hemangioma
Congenital Hemangioma
RICH
PICH
NICH

ABSTRACT

The author present a case of a 23-month-old girl with a vascular soft and violaceous neoformation located in the frontal region at the level of the glabella. Since the parents reported that the lesion had been present since birth, the diagnosis of infantile hemangioma was ruled out. The persistence of the lesion at 12 months still did not allow for a definitive distinction between Non Involuting Congenital Hemangioma (NICH) and Rapid Involuting Congenital Hemangiona (RICH). However, its persistence at 23 months confirmed the definitive diagnosis of NICH.

CORRESPONDING AUTHOR

Amalia Licordari,
Family Pediatrician,
Reggio Calabria,
Italy
e-mail: a.licordari@libero.it

Copyright 2025 © by World Health Academy Publishing House
This publication and/or article is for individual use only and may not be further reproduced without written permission from the copyright holder.
Unauthorized reproduction may result in financial and other penalties
DISCLOSURE: ALL AUTHORS REPORT NO CONFLICTS OF INTEREST RELEVANT TO THIS ARTICLE.

Introduction

Congenital hemangioma is a rare benign vascular tumor, typically characterized by a violaceous coloration and medium to large size, that develops during intrauterine life. Based on its pattern of evolution, congenital hemangiomas are classified into three subtypes:
RICH (Rapidly Involuting Congenital Hemangioma)
NICH (Non-Involuting Congenital Hemangioma)
PICH (Partially Involuting Congenital Hemangioma)

A differential diagnosis among these subtypes can be made after the first 12 months of life. RICH lesions undergo complete involution by this time, whereas NICH remain stable in size. PICH lesions initially regress rapidly during the first year, but then involution halts and the lesion remains unchanged without disappearing, eventually becoming indistinguishable from NICH (1).

Case description

A 23-month-old girl was admitted to the clinic for evaluation of a neoformation measuring approximately 1.5 cm in diameter, located in the frontal region at the level of the glabella. The lesion was elastic in consistency, mobile over the underlying planes, and exhibited a violaceous coloration (Fig. 1). A previously performed ultrasound revealed an anechoic content.

Fig. 1. *The patient at the age of 23 months.*

The initial suspected diagnosis, based primarily on the lesion's color and size, was subcutaneous infantile hemangioma. However, following a thorough medical history, this diagnosis was reconsidered, as the parents reported that the lesion had been present since birth.

Infantile Hemangiomas, whether superficial, subcutaneous, or mixed, are never present at birth. They usually appear in the first weeks of life, go through an initial proliferative phase in the first 4-5 months, followed by a maturation phase that extends up to 12 months of age. Subsequently, a regression phase ensues, usually concluding between 7 and 9 years of age. In this case, the parents were asked to provide photographic documentation to assess the lesion's evolution over time (Fig. 2, 3, 4).

Fig. 2. *The patient at the age of 4 months.*

Fig. 3. *The patient at the age of 9 months.*

Fig. 4. *The patient at the age of 12 months.*

The earliest available images date back to the age of four months, when the lesion was evident but inconclusive for diagnosis. The persistence of the lesion at 12 months still did not allow for a definitive distinction between NICH and RICH. However, its persistence at 23 months confirmed the definitive diagnosis of NICH.

Discussion

Non-Involuting Congenital Hemangiomas (NICH) are characterized by their stability over time, showing neither expansion nor regression. In approximately 10% of cases, postnatal growth may occur, usually proportional to the child's somatic development.

Morphologically, two clinical variants of NICH have been described: one presents as a flat patch with a slightly atrophic surface and firm consistency; the other appears as a nodular or plaque-like lesion, dark red to violet in color, with telangiectasias and a pale peripheral halo. These lesions predominantly affect the head and neck region (43% of cases) and the limbs (38%).

The distinction between infantile hemangiomas and congenital hemangiomas lies not only in their presence at birth and evolutionary behavior, but also in their incidence, sex distribution, coloration, and size (2, 3) (Table I).

Table I. *Comparison between Infantile and Congenital Hemangioma.*

INFANTILE HEMANGIOMAS	CONGENITAL HEMANGIOMAS
Absent at birth	Fully formed and visible at birth
10% incidence	Rare
M/F: 1/4 Primarily located on head and neck	M/F: 1/1 Primarily located on limbs and trunk
Red or bluish nodule Glut-1 positive	Violaceous nodule often with telangiectasias Glut-1 negative
Variable volume Rapid growth phase during first 4-5 months and slow involution	Medium-to-large volume Distinct pattern of evolution: RICH (rapid), PICH (partial), NICH (none)

However, the most defining difference lies in immunohistochemistry. Infantile Hemangiomas are characterized by the presence of a glucose transporter protein (GLUT1) found on erythrocytes, which is absent in Congenital Hemangiomas (2).

This immunohistochemical marker regulates neoangiogenesis and acts as a capillary growth factor. It is normally found only in the placenta and the blood-brain barrier. During childbirth, microemboli containing GLUT-1 may detach from the placenta, enter the newborn's bloodstream, and settle in the skin, erroneously stimulating capillary proliferation for 4–5 months until, having exhausted its function, the marker disappears, causing the cessation of endothelial proliferation.

This hypothesis explains why Infantile Hemangiomas cannot be present at birth, since the microemboli detach from the placenta only during delivery.

Therefore, it can be deduced that the natural history of Infantile Hemangiomas differs from that of Congenital Hemangiomas, as the former are believed to be perinatal proliferative disorders of angioblastic tissue that occur during the final stage of differentiation of the capillary system, while the latter could be due to malformative disorders.

The exact cause is still unknown, though genetic (mutations in GNAQ and GNA11 genes have been described), epigenetic, and environmental factors might be implicated (4,5).

Diagnosis is clinical, and instrumental tests, including ultrasound, are not necessary and often misleading.

What should be communicated to the parents?

1) Non-Involuting Congenital Hemangiomas (NICH) are benign vascular tumors with a good prognosis.

2) They do not require further diagnostic testing, as the diagnosis is clinical.

3) Surgical excision is the only treatment option, considered only if the location of the lesion interferes with the child's relational life. Multidisciplinary specialist evaluation is necessary if the lesion's location may affect organ function.

References

1. Arcangeli F, Baruzzi M, Mambelli L, Marchetti F, Pini I. Pediatrics by acronyms: an infant with RICH. Physician and Child Pg Electronic. 2012; 15(5).

2. Leon-Villapalos J, Wolfe K, Kangesu L. GLUT-1: an extra diagnostic tool to differentiate between haemangiomas and vascular malformations. The British Association of Plastic Surgeon. 2005; 58:348-352.

3. Bonifazi E. Congenital noninvolving hemangioma. European Journal of Pediatric Dermatology. 2012; 22(3):216.

4. Bonifazi E, Cutrone M. Unusually large patch-tipe non involuting Congenital Hemangioma of the shoulder: a report of two cases. Pediatric Dermatolog. 2015; 32(5):710.

5. Enjoras O, Mulliken JB, Boon LM et al. Non Involuting Congenital Hemangioma: a rare cutaneus vascular anomaly. Plast Reconstr Surg. 2001;107(7):1647-54.

INTERNATIONAL JOURNAL
of PEDIATRIC DERMATOLOGY

Special Issue, 2025
ISSN 3035-1006 online

Case Report

What Strange Spots!

Maria Manta[1]

[1]*Pediatrician, AUSL Reggio Emilia, Italy*

KEYWORDS

Dark macules
Ash-gray macules
Ashy dermatosis
Dermatosis cinerea

ABSTRACT

The author presents the case of a 13-year-old boy who had been exhibiting asymptomatic, grayish-brown macules on both upper and lower limbs for approximately one month. The key clinical, dermoscopic, and histopathological findings support an accurate differential diagnosis among conditions with similar presentations.

CORRESPONDING AUTHOR

Maria Manta,
Pediatrician,
AUSL Reggio Emilia,
Italy
e-mail: pediatramanta@gmail.com

Copyright 2025 © by World Health Academy Publishing House
This publication and/or article is for individual use only and may not be further reproduced without written permission from the copyright holder.
Unauthorized reproduction may result in financial and other penalties
DISCLOSURE: ALL AUTHORS REPORT NO CONFLICTS OF INTEREST RELEVANT TO THIS ARTICLE.

Introduction

A 13-year-old boy presented to the clinic for his annual health check-up. For about one month, he has exhibited asymptomatic dark macules on both upper and lower limbs, without fever, signs of inflammation, or itching.

The trunk, palms, soles, face, and mucous membranes are unaffected. The patient is not taking any medications and has no history of previous dermatological conditions.

The lesions are symmetrically distributed on both the upper limbs (Fig. 1) and lower limbs (Fig. 2).

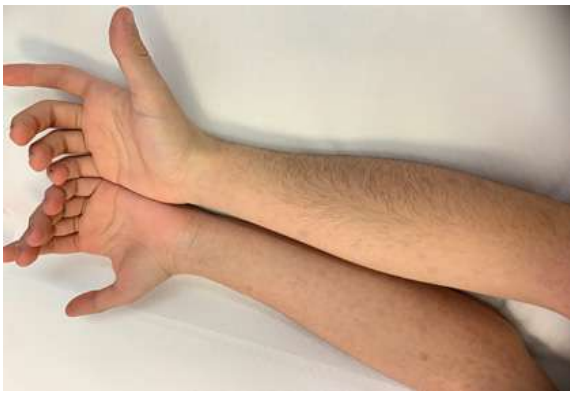

Fig. 1. *Gray macules on the upper limbs.*

Fig. 2. *Gray macules on the lower limbs.*

The main and most frequent conditions to consider in the differential diagnosis are:

- Pityriasis rotunda
- Terra firma-forme dermatosis
- Acanthosis nigricans
- Pityriasis rosea of Gibert
- Pityriasis versicolor
- Ashy dermatosis

Discussion

Pityriasis rotunda

This is a genetically transmitted condition, typically observed in the Sardinian population. It is a benign disorder characterized by oval or round, hypopigmented lesions that tend to resolve spontaneously after puberty. It can be considered a genodermatosis, likely related to geographic isolation.

Terra firma-forme dermatosis

This is a form of hyperkeratosis that resembles dirty skin, presenting as 'dark patches' on the neck, trunk, and limbs. It is not removed by regular cleansing with soap and water but can be effectively removed using a cotton swab soaked in alcohol or nail polish remover (acetone).

Acanthosis nigricans

Acanthosis nigricans is a cutaneous condition typically found in individuals with obesity and type 2 diabetes mellitus, associated with insulin resistance. It is characterized by dark, hyperpigmented, almost velvety plaques due to epidermal hypertrophy. The most commonly affected areas are the neck and axillae. Dermoscopy reveals a papillomatous surface with accentuated skin furrows forming polygonal patterns.

Pityriasis rosea of Gibert

This is a skin condition that begins with a single "herald patch," followed by the appearance of multiple oval-shaped lesions, predominantly on the trunk. Under dermoscopy, a well-defined collarette of scale (epidermolytic border) can be observed. The lesions are pink rather than ash-gray in color and, in the classic form, follow a characteristic "Christmas tree" distribution on the trunk.

Pityriasis versicolor

This is a common fungal infection, often occurring in summer and autumn. It presents with multiple roundish patches of variable color and is sometimes associated with pruritus. Under Wood's lamp examination, Pityrosporum fluoresces with a characteristic yellow-green hue.

Ashy dermatosis (dermatosis cinerea)

Ashy dermatosis is characterized by asymptomatic ash-gray macules symmetrically distributed on the limbs, trunk, neck, and face. Unilateral presentation and mucosal involvement have also been described.

Diagnosis

Ashy dermatosis

Ashy dermatosis, also known as dermatosis cinerea, is characterized by asymptomatic ash-gray macules symmetrically distributed on the limbs, trunk, neck, and face (1). Unilateral forms and mucosal involvement have also been reported (2). It most frequently affects individuals in the second decade of life. The etiology is unknown, although it is often associated with previous infections, drug intake, or genetic factors (3).

The most striking features are the grayish coloration of the lesions, the symmetrical distribution over the affected areas, the sparing of the palms, soles, scalp, and mucous membranes, and the absence of symptoms or associated conditions.

On dermoscopic examination (Fig. 3), melanin granules can be observed in the deeper dermis, which visually imparts a bluish-gray color to the affected areas (4).

Fig. 3. *Dermoscopic examination shows the presence of fine granules with a gray hue.*

Histological examination is sometimes performed solely to exclude other conditions, as findings are non-specific. It reveals basal layer cells containing numerous melanin-filled vacuoles, the presence of melanophages in the dermis, and a leukocytic infiltrate at the basal layer.

Ashy dermatosis, or dermatosis cinerea, does not pose any health risk to the patient. It is primarily an aesthetic issue, but it can have psychological consequences and social implications.

In some cases, it may be appropriate to attempt therapeutic intervention, although there is no standardized treatment strategy that consistently resolves the condition.

Some therapeutic benefit has been reported with clofazimine, topical tacrolimus, oral dapsone, phototherapy, oral isotretinoin and antioxidants (Vitamin C and Vitamin E).

Conclusion

Ashy dermatosis is a rare condition among Caucasian individuals. It is more commonly observed in patients with Fitzpatrick skin phototypes III-V, i.e., those with darker skin tones.

The patient in our clinical case represents an uncommon occurrence, but in the context of an increasingly multiethnic society, we are likely to encounter this condition more frequently. Early recognition is important due to its potential social impact and the resulting negative effect on patients' quality of life.

References

1. Nguyen K, Khachemoune A. Ashy dermatosis: a review. Dermatol Online J. 2019; 25(5):13030/qt44f462s8.
2. Rato M, Monteiro AF, Aranha J, Tavares E. Ashy dermatosis with involvement of mucous membranes. An Bras Dermatol. 2017; 92(5 Suppl 1):17-20. doi: 10.1590/abd1806-4841.20176133.
3. M. Cutrone. Erythema dyschromicum perstans (Ashy dermatitis). Medico e Bambino pagine elettroniche 1999; 2(9).
4. Kamano S, Hotta E, Goto S, Inagawa M. Ashy Dermatosis in a Two-Year-Old Child: A Case Report and Mini-Review. Acta dermatovenerologica Croatica. 2023; 31(1):32-35.

INTERNATIONAL JOURNAL
of PEDIATRIC DERMATOLOGY

Special Issue, 2025
ISSN 3035-1006 online

Case Report

Is Alopecia Always Areata?

Antonio Iannone[1]

[1]*Pediatrician, ASST Valtellina ed Alto Lario, Sondrio, Italy*

KEYWORDS

Trichotillomania
Impulse control disorder
Psychiatric disorder
Alopecia areata
Congenital triangular alopecia
Tinea capitis
Androgenetic alopecia,
Dermoscopy
Trichoscopy

CORRESPONDING AUTHOR

Antonio Iannone,
Pediatrician,
ASST Valtellina ed Alto Lario,
Sondrio, Italy
e-mail: iannoneant.dott@tiscali.it

ABSTRACT

We report the case of a 6-year-old child presenting with alopecia in the right frontotemporal region. Dermoscopic examination revealed broken hairs at varying lengths and the presence of intact hairs within the area of alopecia, which exhibited a markedly irregular shape. The main clinical and dermoscopic features of alopecia patterns relevant to the differential diagnosis are discussed.

Copyright 2025 © by World Health Academy Publishing House
This publication and/or article is for individual use only and may not be further reproduced without written permission from the copyright holder.
Unauthorized reproduction may result in financial and other penalties
DISCLOSURE: ALL AUTHORS REPORT NO CONFLICTS OF INTEREST RELEVANT TO THIS ARTICLE.

Introduction

Trichotillomania, also called hair-pulling disorder, is defined by the Diagnostic and Statistical Manual of Mental Disorders (DSM-V) as an obsessive-compulsive or related disorder in which subjects recurrently pull out hair from any region of their body, resulting in hair loss (1).

Case Report

A 6-year-old boy presented with an irregularly shaped area of hair thinning in the right frontotemporal region. Hairs of varying lengths were visible, with no surface skin alterations. Trichoscopic examination revealed hairs broken at different lengths, intact hairs within the affected area, and follicular hair residues ("black dots") (Fig.1, 2).

The clinical and trichoscopic findings were characteristic of trichotillomania.

Fig. 1. *Right fronto-temporal alopecia.*

Fig. 2. *Trichoscopy: no surface alterations, hair broken at different heights, intact hair inside the patch, follicular hair residues.*

Discussion

Trichotillomania is an obsessive-compulsive disorder that clinically presents with single or multiple patches of alopecia with irregular or bizarre shapes. These are most commonly located in the frontoparietal region, but can also affect the eyebrows, upper eyelashes, and pubic area. The presence of hairs broken at different lengths is a hallmark of the condition. It predominantly affects school-age children and is more frequent in females. Parents often have difficulty accepting the diagnosis.

On trichoscopy, the most specific and suggestive features include hairs broken at various lengths, trichoptilosis (split ends), hook hairs (proximally twisted and contracted hairs with irregular shapes), black dots (follicular hair residues), and very short broken hairs with variable diameter, shape, and distribution (2).

Differential Diagnosis

Trichotillomania must be distinguished from several other causes of pediatric alopecia, including (Tab. I):

- Congenital triangular alopecia, often present at birth but sometimes not noticed until the child is 3-4 years old. It is easily recognized clinically and presents as a triangular patch of hair thinning with the apex pointing upward toward the vertex, although the shape may also be rhomboid, lanceolate, or oval. It is most frequently localized in the temporo-parietal area, usually unilaterally, and more rarely bilaterally or in the occipital

region.

Trichoscopy shows hairs of varying lengths, fine and soft, often described as "vellus" hairs, with no signs of inflammation on the underlying scalp. Parents should be reassured of its benign and non-progressive nature, and no treatment is necessary (3, 4);

- **Tinea capitis** typically presents with one or more round patches of varying size, erythematous and scaly, with surface alterations such as redness, scaling, and crusts, along with broken hairs.

Diagnosis is clinical; fungal culture may be helpful, although trichoscopy is not strictly required. When performed, it may reveal characteristic features such as Morse code hairs, comma hairs, corkscrew hairs, and hair casts (peripilar sleeves), as well as black dots (5, 6);

- **Androgenetic alopecia** is characterized by progressive thinning of the hair, primarily in the frontal and vertex regions. There are no surface changes, no broken hairs, and no exclamation mark hairs. The most important diagnostic feature is a variation in hair shaft diameter greater than 20% (miniaturization > 20%);

- **Alopecia areata** can sometimes be difficult to distinguish from trichotillomania. It presents with hairs broken at the base but typically all at the same level. Trichoscopy reveals follicular residues (black dots) and the pathognomonic "exclamation mark hairs" (Table II).

Table I. *Different types of alopecia and their dermoscopic features.*

Table II. *Differences Between Trichotillomania and Alopecia Areata.*

Trichotillomania	Alopecia Areata
Irregular patch	Rounded patch
• Hairs broken at different lengths • Intact hairs within the patch • Follicular hair residues (Black dots) • Exclamation mark hairs absent	• Broken hairs • No intact hairs within the patch • Exclamation mark hairs present • Follicular hair residues (Black dots) • Yellow dots (chronic phase)

Conclusion

Clinical observation, supported by trichoscopy, is an essential tool for distinguishing trichotillomania from other forms of non-scarring alopecia, such as alopecia areata or scalp infections.

In this context, the pediatrician plays a central role, often representing the first point of contact for the patient and their family. It is therefore crucial that pediatricians are able to recognize early clinical and behavioral signs of trichotillomania.

References

1. Melo DF, Lima CDS, Piraccini BM, Tosti A. Trichotillomania: What Do We Know So Far? Skin Appendage Disord. 2022; 8(1):1-7. doi: 10.1159/000518191.
2. Martin JM, Montesinos E, Cordero P et al. Trichoscopy features of trichotillomania. Pediatr Dermatol. 2019; 36(2):265-26.
3. Starace M et al. Atypical presentation of congenital triangular alopecia: a case series in Italy. Dermatol Pract Concept. 2020;10(4).
4. Guan Z et al. Clinical and dermatoscopic features of temporal triangular alopecia in infants. Skin Res Technol. 2023; 29(3). doi:10.1111/srt.13294.
5. Lacarrubba F, Verzì AE, Micali G. Newly described features resulting from high-magnification dermoscopy of tinea capitis. JAMA Dermatol. 2015; 151(3):308-10. doi: 10.1001/jamadermatol.2014.3313.
6. Waśkiel-Burnat A, Rakowska A, Sikora M, Ciechanowicz P, Olszewska M, Rudnicka L. Trichoscopy of Tinea Capitis: A Systematic Review. Dermatol Ther (Heidelb). 2020; 10(1):43-52. doi: 10.1007/s13555-019-00350-1.

INTERNATIONAL JOURNAL
of PEDIATRIC DERMATOLOGY

Special Issue, 2025
ISSN 3035-1006 online

Case Report

Marine Irritants. Two Case Reports

Flavio Magliani[1]

[1]*Pediatrician, G. Marconi University, Rome, Italy*

KEYWORDS

Sea environmental changes
Stinging marine organism
Jellyfish dermatitis
Pelagia noctiluca
Cnidarians

ABSTRACT

Climate change and eutrophication have contributed to an increased prevalence of marine stinging organisms and jellyfish in Italian coastal waters. Among these, Pelagia noctiluca is known to induce contact dermatitis. This report presents two clinically analogous cases observed in the Tyrrhenian and Adriatic Seas, and outlines the most effective strategies for symptom management and prevention of potential worsening.

CORRESPONDING AUTHOR

Flavio Magliani,
Pediatrician,
Guglielmo Marconi University,
Rome, Italy
tel: +39.3357902912
e-mail: fmagliani@libero.it

Copyright 2025 © by World Health Academy Publishing House
This publication and/or article is for individual use only and may not be further reproduced without written permission from the copyright holder.
Unauthorized reproduction may result in financial and other penalties
DISCLOSURE: ALL AUTHORS REPORT NO CONFLICTS OF INTEREST RELEVANT TO THIS ARTICLE.

Introduction

With the arrival of the summer season, days at the beach provide many families with an opportunity for recreation, but these seemingly carefree moments can turn into unpleasant experiences, especially for young children, due to accidental contact with stinging marine organisms. It is the task of child health professionals to educate parents about these potential risks and how to behave. Over the last 20 years, the Mediterranean Sea has undergone profound environmental changes, including an increase in water temperature, a decrease in biodiversity and excessive eutrophication, which have led to the proliferation of marine species that are potentially dangerous to humans (1). In particular, water temperatures have reached in Italy 30 °C, a biologically significant value that has altered the balance of the marine ecosystem, favouring the growth of stinging organisms in the absence of their natural predators, and causing a sharp depletion of fish stocks.

In our clinics, we regularly see children with lesions from contact with stinging marine animals capable of injecting toxic proteins. These lesions are mostly linear in expression, like the tentacles of Cnidarians, and after a very early erythematous-pomphoid itchy phase, they evolve into vesicles that break off to form scabs and often become infected.

Of these cases we report two.

Case 1

A 7-year-old boy from Lazio (Tyrrhenian Sea) presented to our clinic with a painful, exudative erythematous lesion (Fig. 1) located on the anterior surface of the right leg. The lesion had appeared following contact with Pelagia noctiluca during a sea swim two days earlier. Despite treatment with topical antibiotics and corticosteroids, the lesion deepened in the following days, forming a superficial eschar and eventually healed with scarring after approximately 12 days.

Fig. 1. *Exudative erythematous lesion on the right leg after contact with Pelagia noctiluca.*

Case 2

The second case, reported from the Veneto region (Adriatic Sea), serves as a clear example of what should be avoided. It concern a two-year-old girl whose parents had placed her in a shallow pool they had dug in the sand and filled with seawater, unaware that jellyfish were present. After coming into contact with a stinging marine organism, she suddenly cried out. In an attempt to soothe her, her parents poured seawater over the reddened area on her left thight. Unfortunately, they then rubbed the affected area with hot sand, which significantly aggravated the lesion due to the rupture of nematocysts (Fig. 2).

Fig. 2. *Skin lesion on the left thigh after contact with Pelagia noctiluca.*

Discussion

These cases highlight the importance of providing families with accurate information to prevent potentially harmful actions. Among the most notable stinging marine organisms is *Pelagia noctiluca*, a jellyfish commonly found in our seas, with tentacles exceeding one meter in length. These tentacles contain toxic compounds such as congestin, thalassin, and hypnosin, which, upon contact with human skin, can provoke localized inflammatory reactions and, in some cases, systemic symptoms, depending on individual sensitivity and the quantity of venom introduced.

Not all jellyfish are dangerous; however, certain species, such as *Physalia physalis*, also known as the Portuguese man o' war, pose significant risks. Others, like *Rhizostoma pulmo* and *Cotylorhiza tuberculata*, are more visible and generally less harmful (2). Accidental contact is common, since tentacles are often transparent and may extend over a meter in length. For this reason, it's crucial to prevent contact by avoiding swimming in areas where jellyfish or their remnants are visible and by teaching both children and parents to refrain from touching stranded animals or their seemingly harmless fragments. Wearing suitable protective clothing during bathing is also advisable.

If contact occurs, the affected area should be rinsed thoroughly with seawater, which neutralizes and flushes away residual nematocysts, rather than fresh water, which can trigger venom release and worsen the injury due to osmotic rupture of the stinging cells. It is equally important not to scratch or rub the affected area. Appropriate topical treatments containing aluminium chloride can help soothe the skin, and systemic analgesics or corticosteroids may be required to control severe pain (3).

Systemic reactions, such as diffuse urticaria or bronchospasm, require immediate intervention following allergology protocols. Beyond jellyfish, other stinging or harmful marine organisms include sea anemones and actinias, with stinging capabilities comparable to jellyfish, sea urchins, whose spines, if left embedded, may lead to granulomatous skin lesions, and fish with venomous spines such as weever fish (tracine), scorpionfish, and stingrays.

A recently reported species in the Mediterranean is *Hermodice carunculata*, commonly known as the "vermocane." This alien, tropical-origin organism often washes ashore after sea storms and can grow up to 60 centimeters in length. Contact with its bristles causes painful, erythematous-pomphoid skin lesions similar to those provoked by the terrestrial processionary moth. The recommended response is to gently remove the bristles using adhesive strips or tape, followed by administration of analgesic and anti-inflammatory treatments.

Another lesser-known but clinically relevant condition is 'swimmer's itch', a dermatitis resulting from transcutaneous penetration by the larvae of trematodes (cercariae), parasites commonly hosted by waterfowl. Though typically found in lakes and rivers, cases have occasionally been reported in tropical marine environments. Humans are aberrant hosts in these scenarios: the larvae fail to complete their life cycle but trigger the appearance of erythematous, intensely itchy papules. Treatment consists of vigorous showering and rubbing, followed by the application of anti-inflammatory ointments.

References

1. Dhillon J, Parker ER. Climate change, harmful algal blooms, and cutaneous disease. JAAD Reviews. 2025; 4:156-166. doi:10.1016/j.jdrv.2025.02.012.
2. Kokelj F, Plozzer C. Irritant contact dermatitis from the jellyfish Rhizostoma pulmo. Contact Dermatitis (01051873). 2002; 46(3):179-180. doi:10.1034/j.1600-0536.2002.460313.x.
3. Bingbing Li, Yueyue Li, Zhiwen Qiu, et al. Advances in Jellyfish Sting Mechanisms and Treatment Strategies. Marine Drugs. 2025; 23(6):231. doi:10.3390/md23060231.

Copyright © 2025 World Health Academy Publishing House srls

All rights reserved.

ISSN 3035-1006 (online)